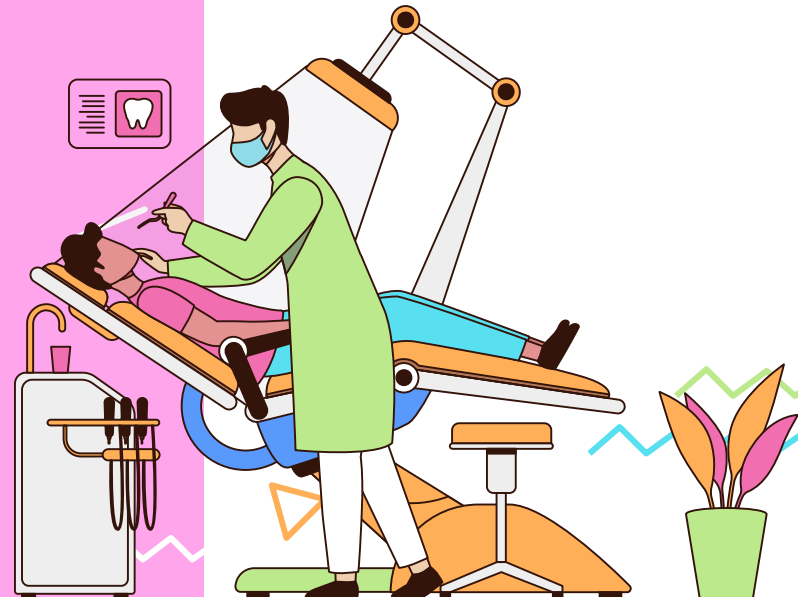

Advanced methods in caries detection and diagnosis

Assist. Prof. Aseel Haidar




Advances in pediatric dentistry have led to improved treatment for children with cavities, gingival disease, and other dental problems.


New technologies such as digital X-rays, laser treatments, and 3D imaging have made it easier for pediatric dentists to diagnose and treat dental issues quickly and accurately.

In addition, advances in dental materials have made it possible for pediatric dentists to provide more comfortable and aesthetically pleasing treatments.






Introduction



**Conventional caries
detection methods**



**Advanced caries
detection
methods**

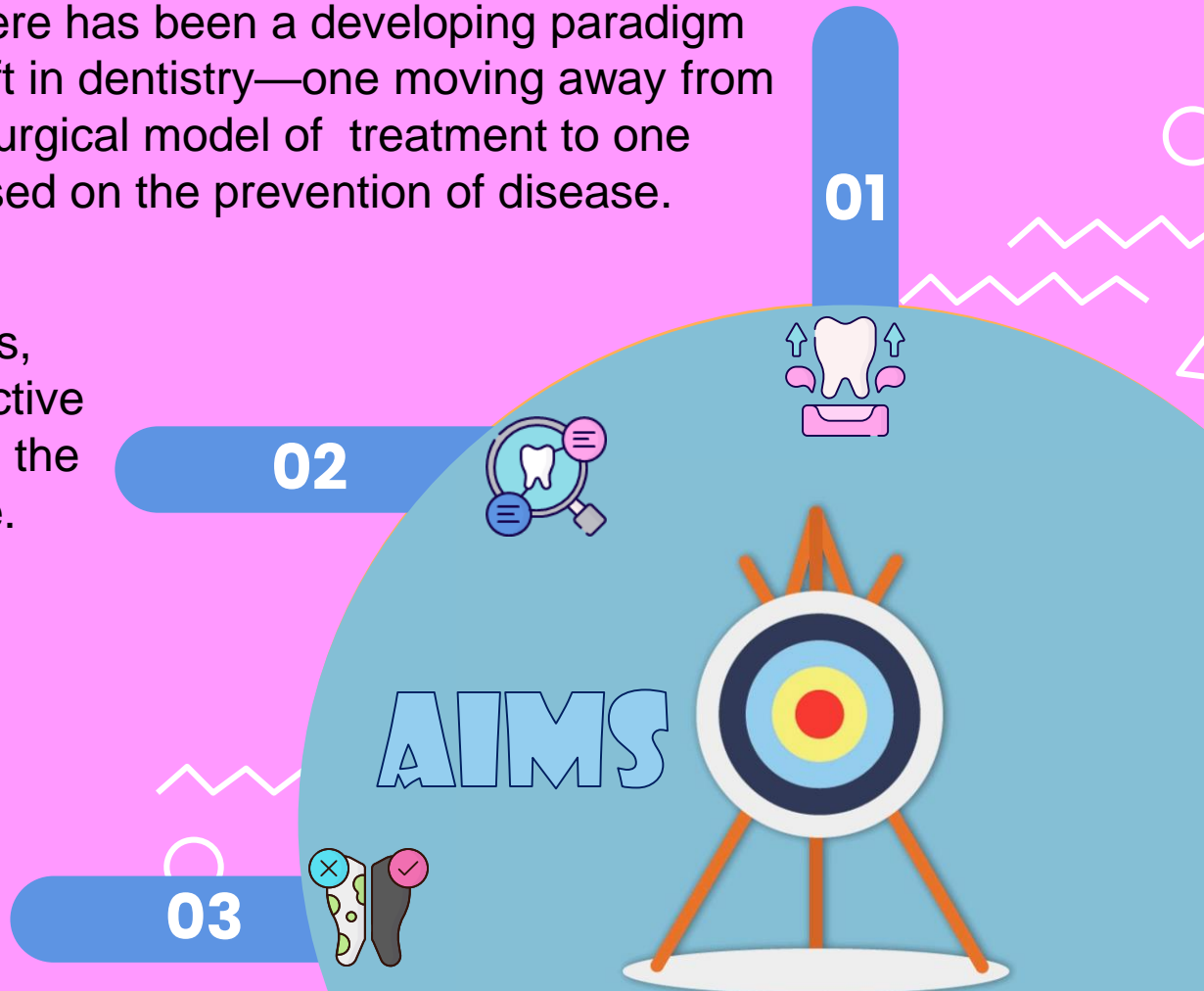
CONTENT



- There has been a developing paradigm shift in dentistry—one moving away from a surgical model of treatment to one based on the prevention of disease.

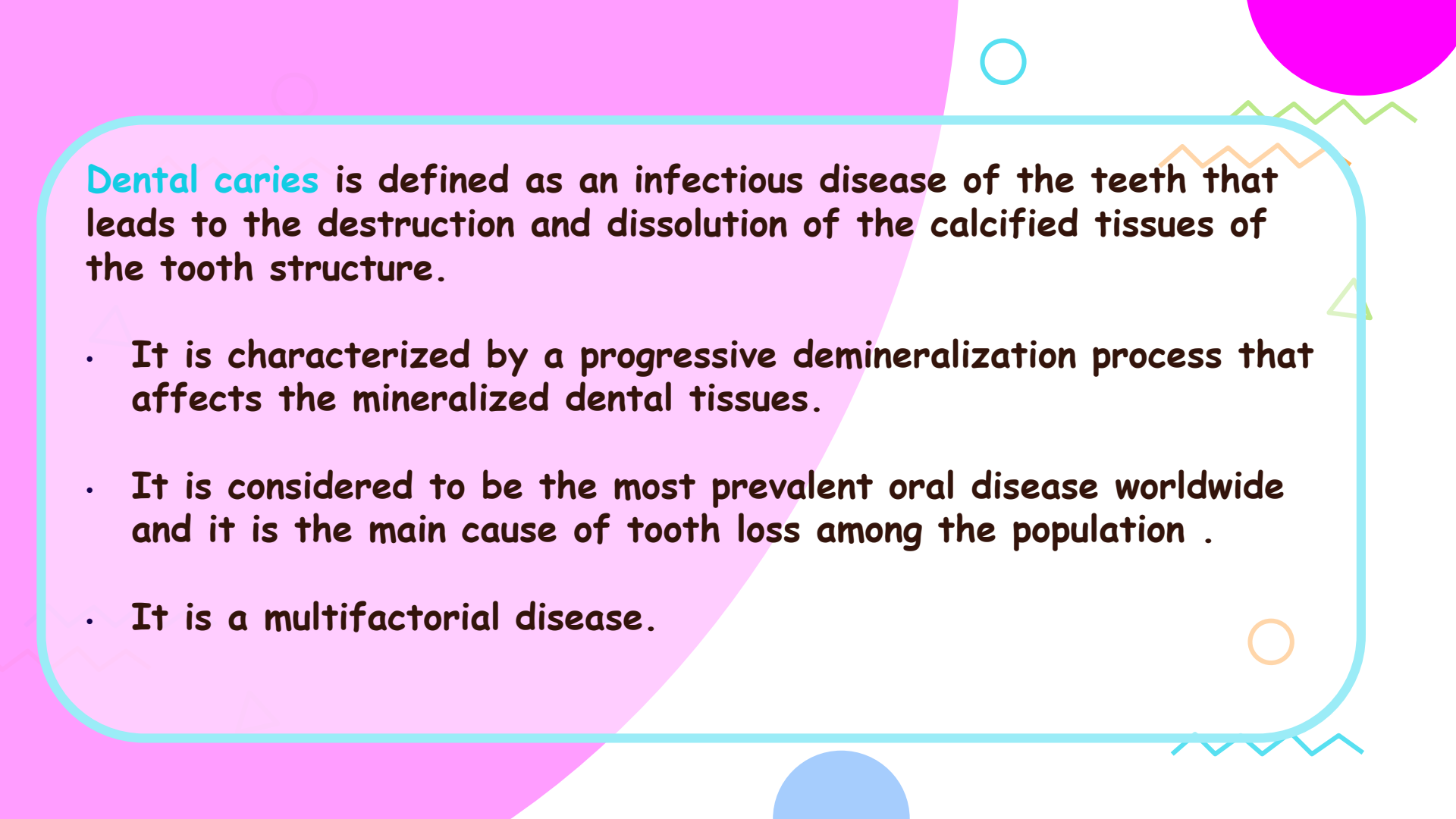
- As with many disease entities, prevention is at its most effective when detection is early within the natural history of the disease.

- The failure to detect early caries, leaving those detectable only at the deep enamel, or cavitated stage.



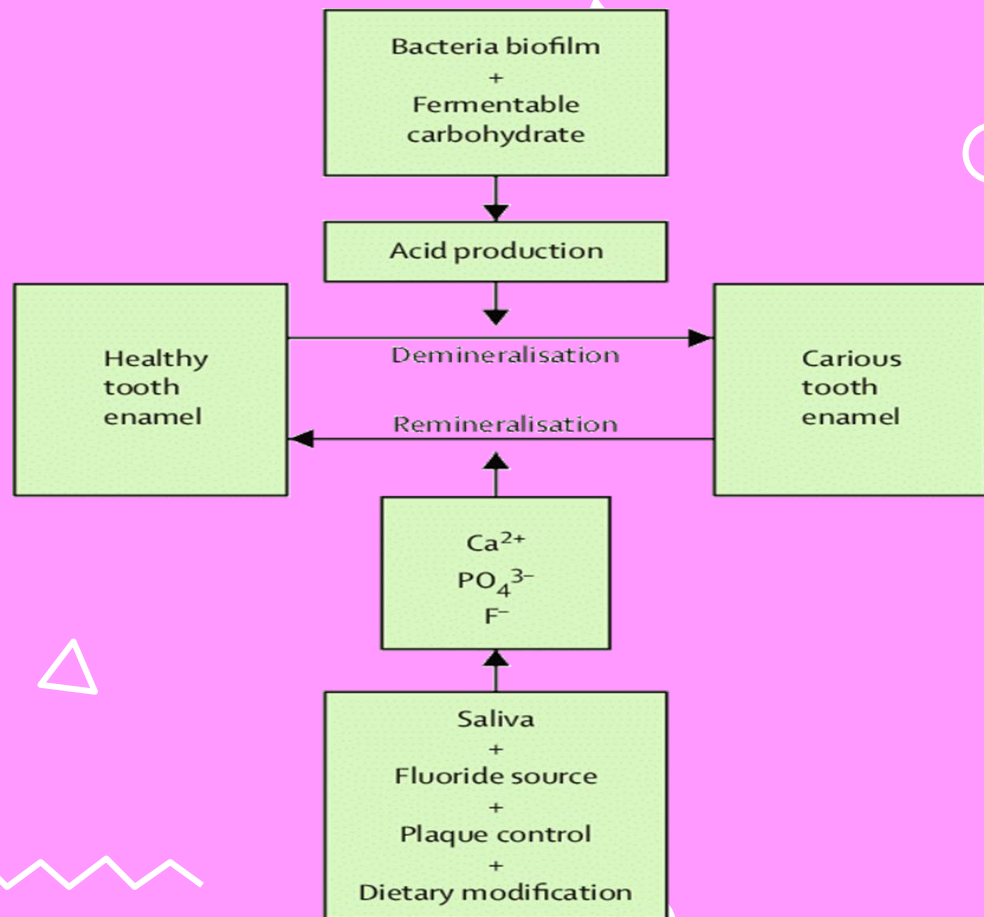
Introduction



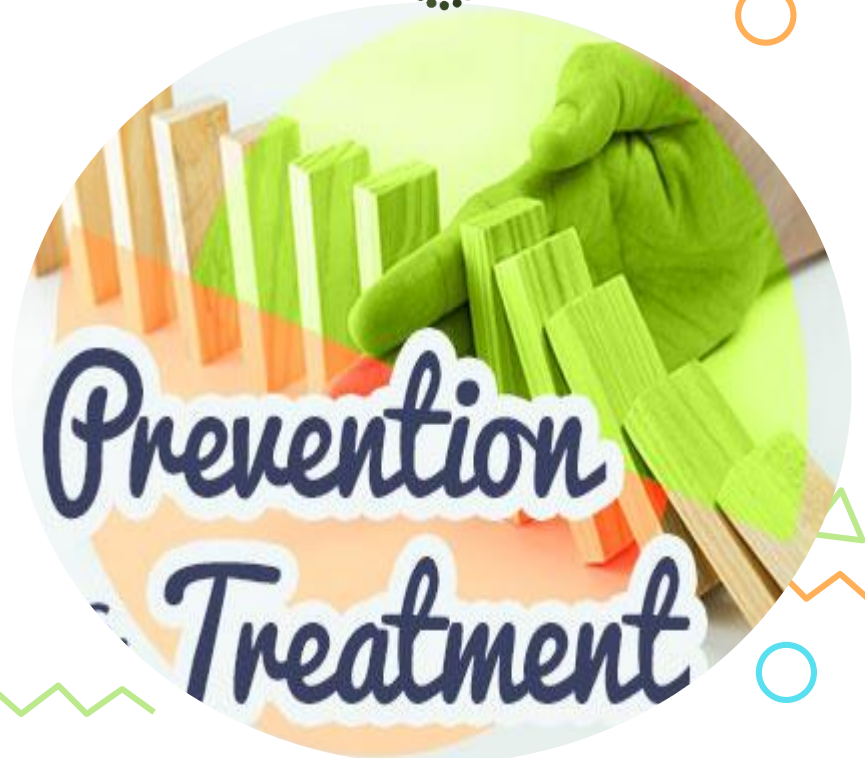

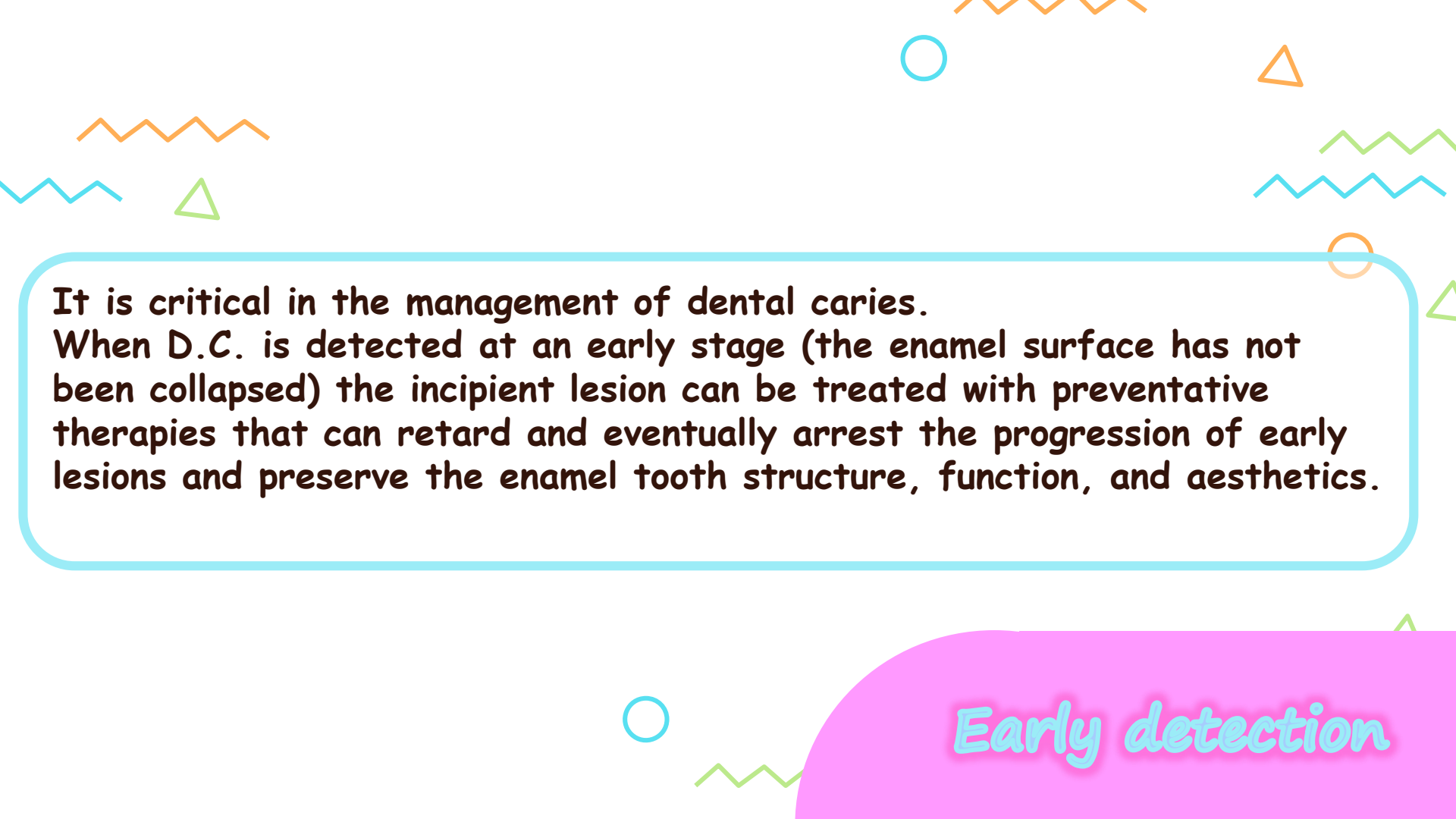
Dental caries is defined as an infectious disease of the teeth that leads to the destruction and dissolution of the calcified tissues of the tooth structure.

- It is characterized by a progressive demineralization process that affects the mineralized dental tissues.
- It is considered to be the most prevalent oral disease worldwide and it is the main cause of tooth loss among the population .
- It is a multifactorial disease.



There has been a creating interest in dentistry that is moving away from **the treatment of the disease to one based on the prevention of it.** Concerning some other diseases, prevention is best when the detection of the disease is early.



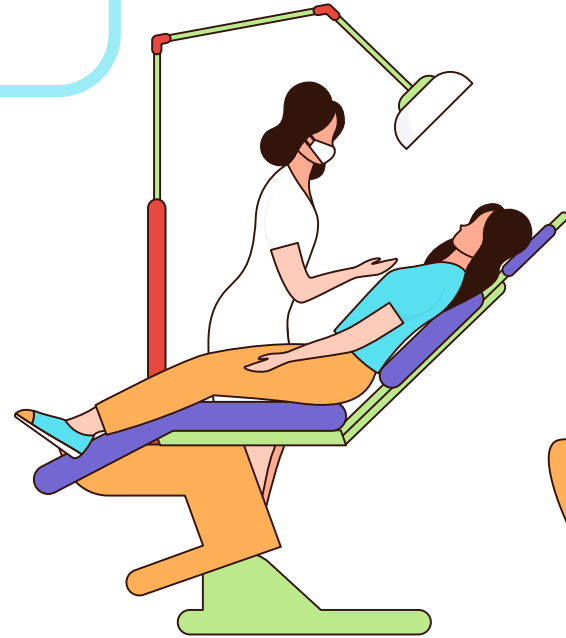

It is critical in the management of dental caries. When D.C. is detected at an early stage (the enamel surface has not been collapsed) the incipient lesion can be treated with preventative therapies that can retard and eventually arrest the progression of early lesions and preserve the enamel tooth structure, function, and aesthetics.

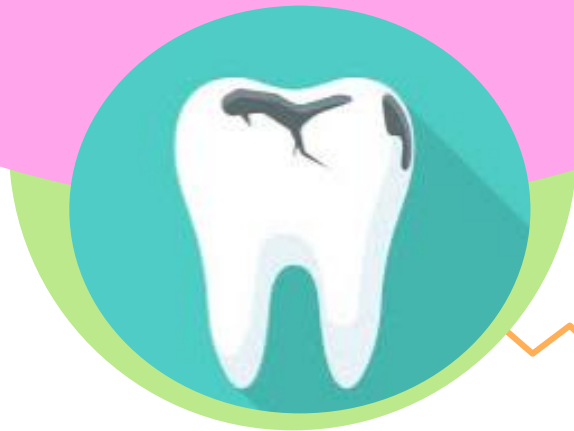Early detection

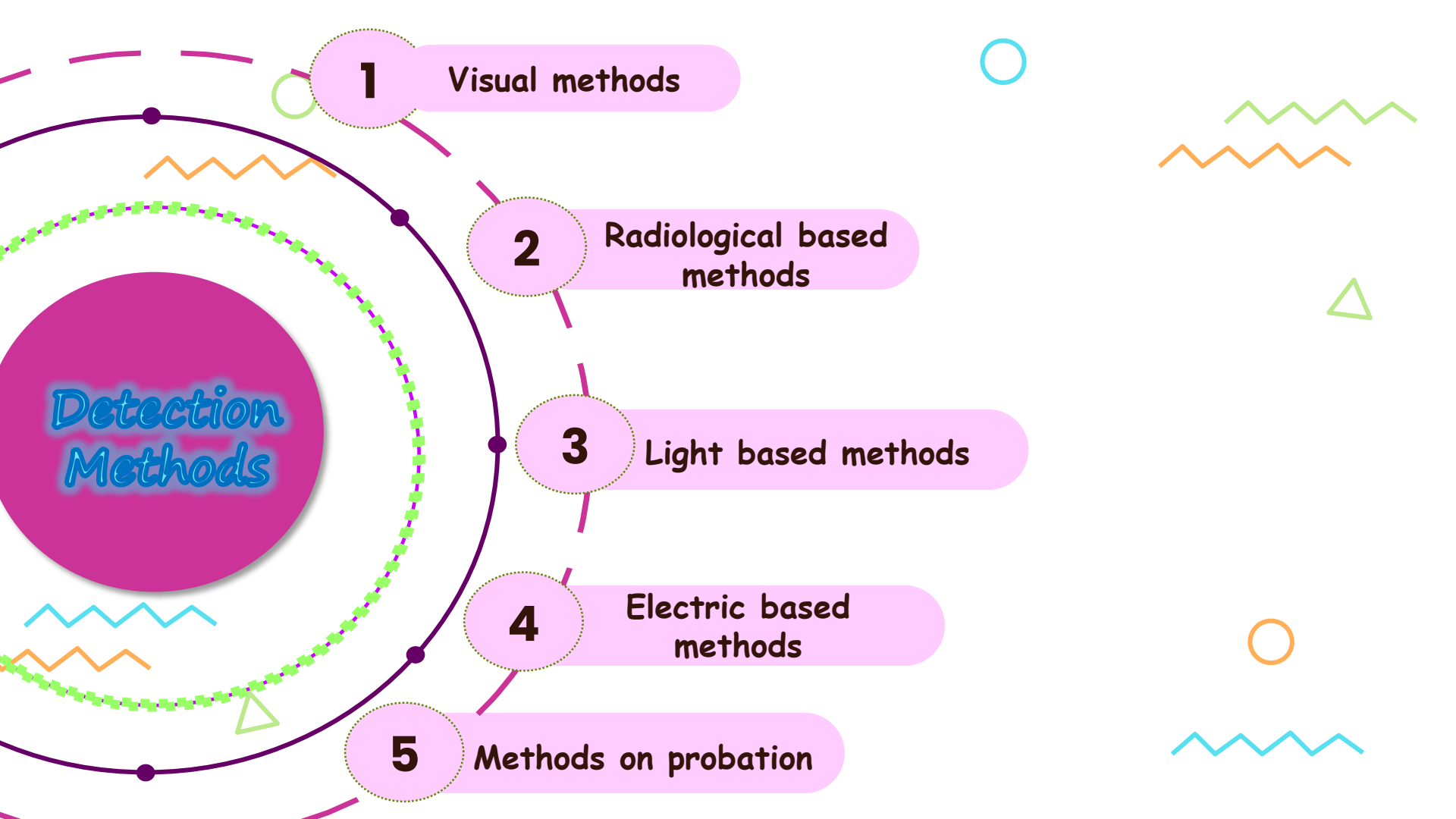
Visual detection and Visual-tactile strategies utilizing the dental explorers and air drying with amplification and radiographs are the regular methods generally utilized for detection of caries .

Conventional
methods



Caries Detection Methods








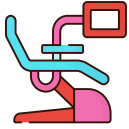Novel diagnostic systems are based upon the measurement of a physical signal these are substitute measures of the caries process.

Examples of the physical signals that can be used in this way include X-rays, visible light, laser light, electrical current, ultrasound, and possibly surface roughness.

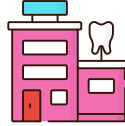For a caries detection device to function, it must be capable of initiating and receiving the signal as well as being able to interpret the strength of the signal in a meaningful way.



1- Visual Caries Detection Methods



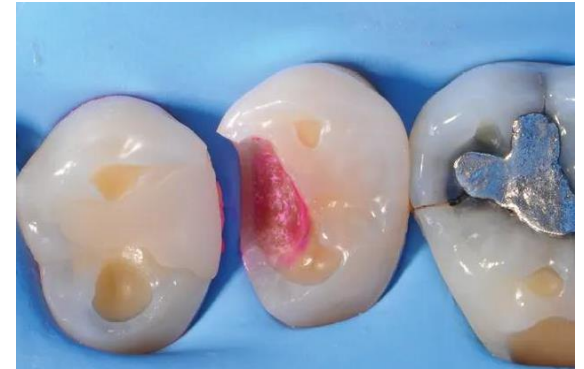
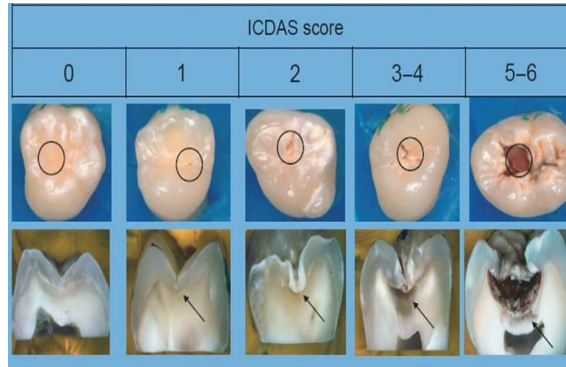
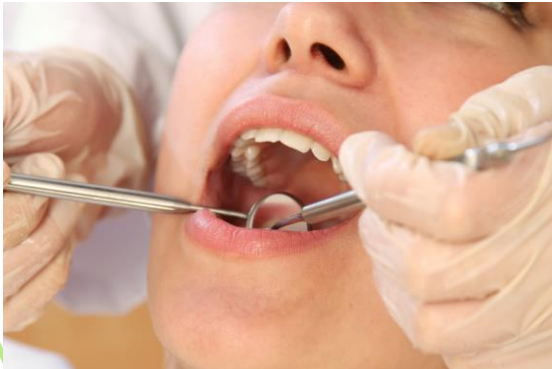Conventional visual inspection



ICDAS

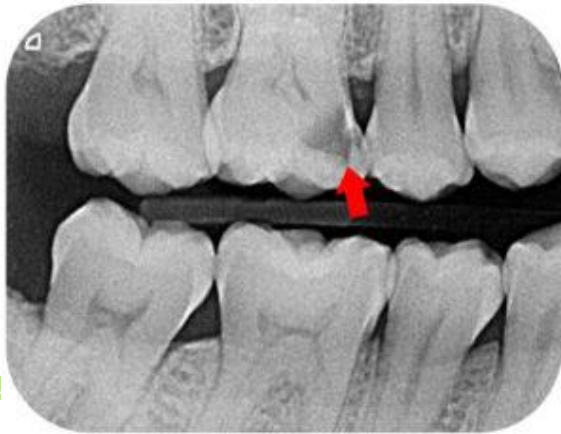


Caries detection dyes

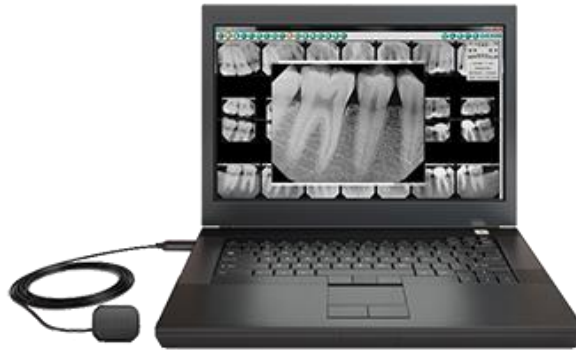

2- Radiology Based Caries Detection Methods

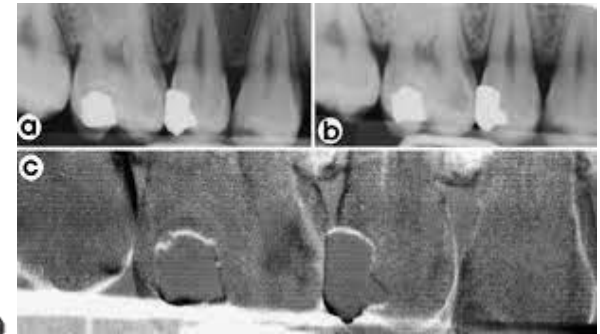
Conventional radiographs



Digital radiographs



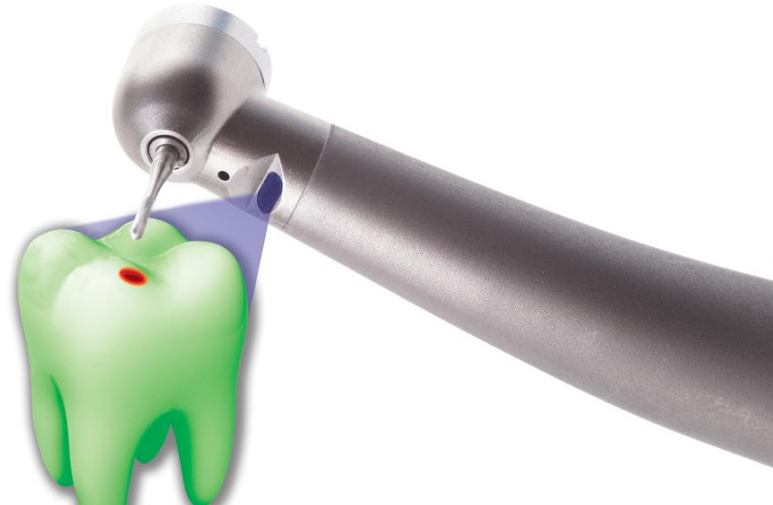

Digital subtraction radiographs



3- Light Based Caries Detection Methods

A- Fluorescence – Aided Caries Excavation (FACE)

- FACE works by exposing carious dentin to purple light of the wavelength of 405 nm and it presents as a red fluorescence.
- Non-carious areas show a green fluorescence



3- Light Based Caries Detection Methods

A- Fluorescence – Aided Caries Excavation (FACE)

- FACE works by exposing carious dentin to purple light of the wavelength of 405 nm and it presents as a red fluorescence.
- Non-carious areas show a green fluorescence

