



CBCT in Diagnosis of Periapical Lesions

Prof. Hussain Faisal Al-Huwaizi

College of Dentistry-University of Baghdad

Chairman of the scientific committee, Iraqi Dental Association

Coordinator of the Iraqi Endodontic Society

Member in the European society of Endodontology

Member in the International, Asian Pacific and Arab endodontic societies

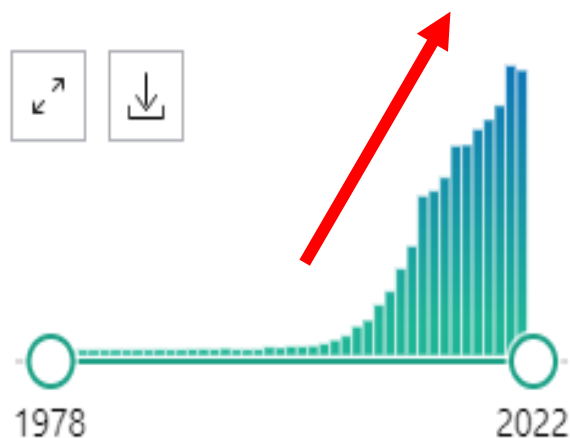
Sorted by: Best match

MY NCBI FILTERS

14,995 results

 Page of 1,500

RESULTS BY YEAR



Cone Beam Computed Tomography.

1

Nasseh I, Al-Rawi W.

Cite

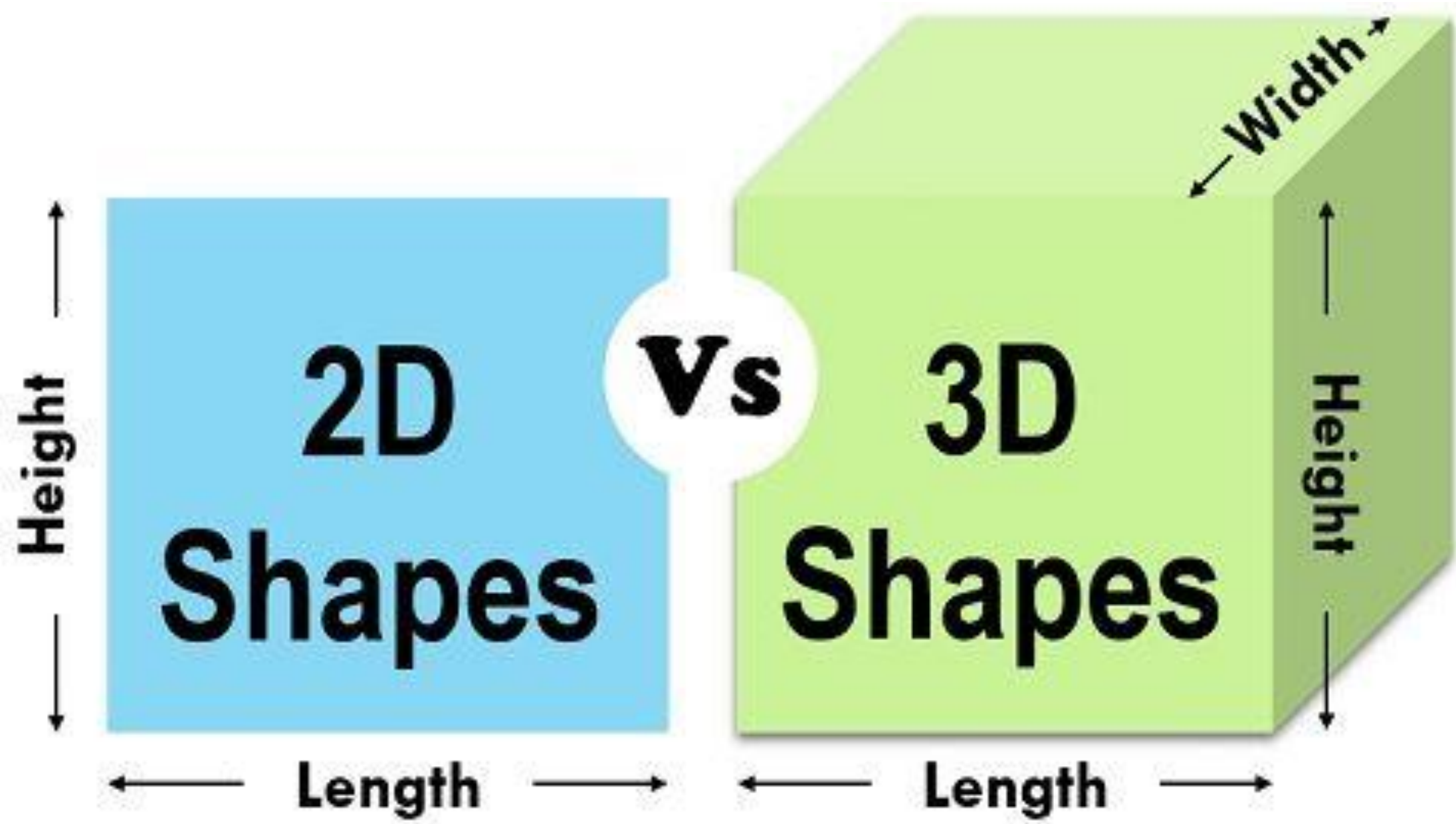
Dent Clin North Am. 2018 Jul;62(3):361-391. doi: 10.1016/j.cden.2018.03.002.

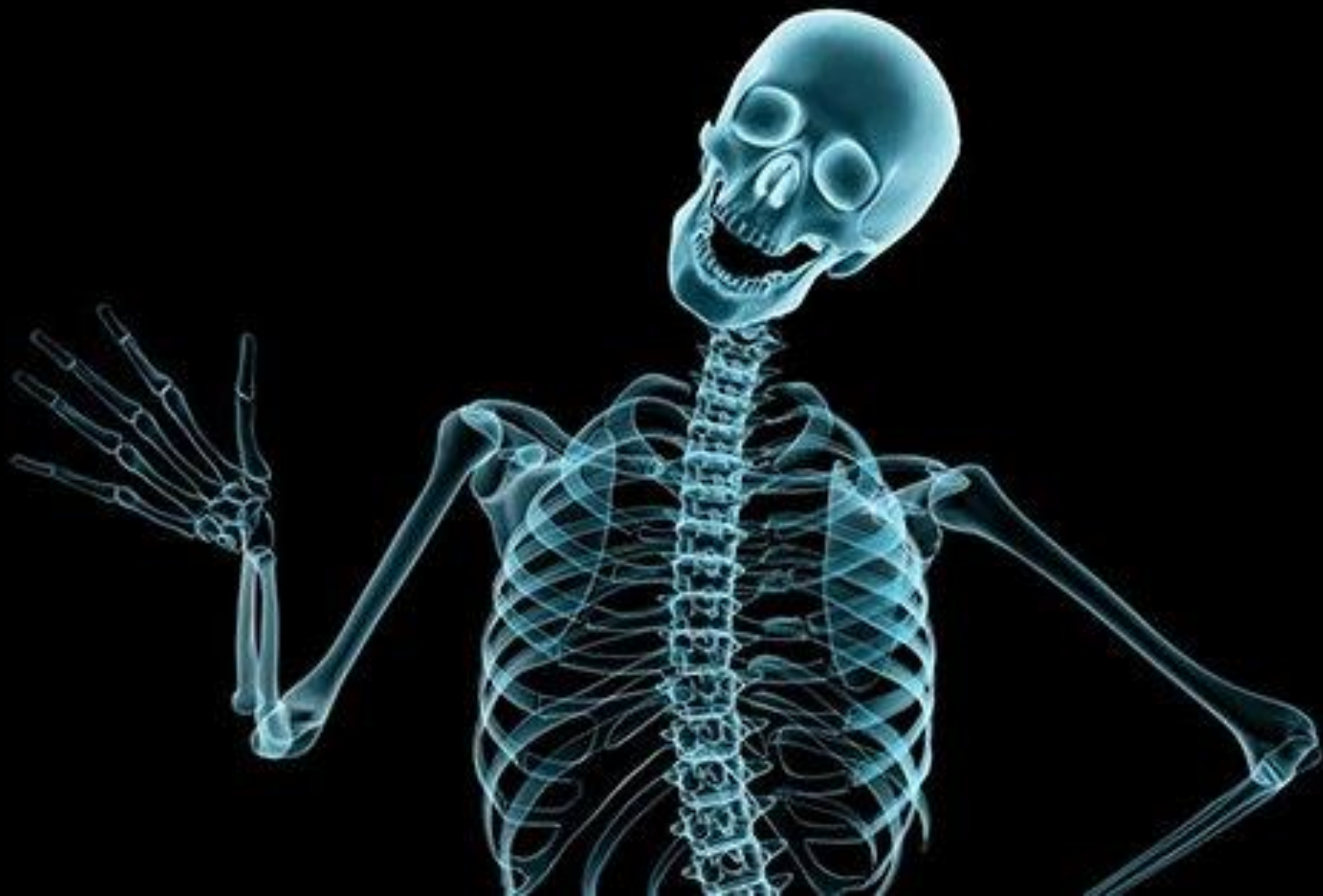PMID: 29903556 [Review](#).

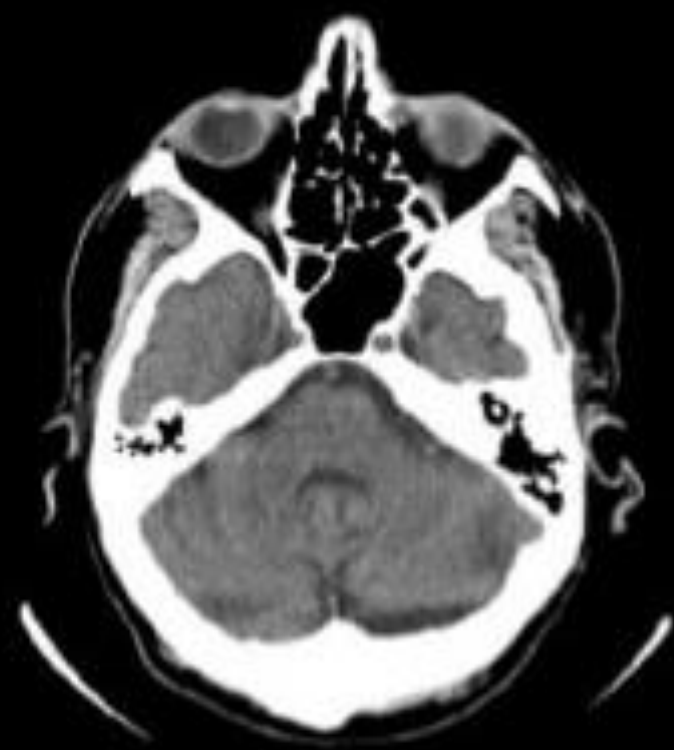Share

In the last several decades, the need for 3D images in dentistry have developed. Computerized **tomography** was first introduced mainly with the advent of implantology, but its use remained limited to a small number of specialists, due to its indications, access and dose radi ...

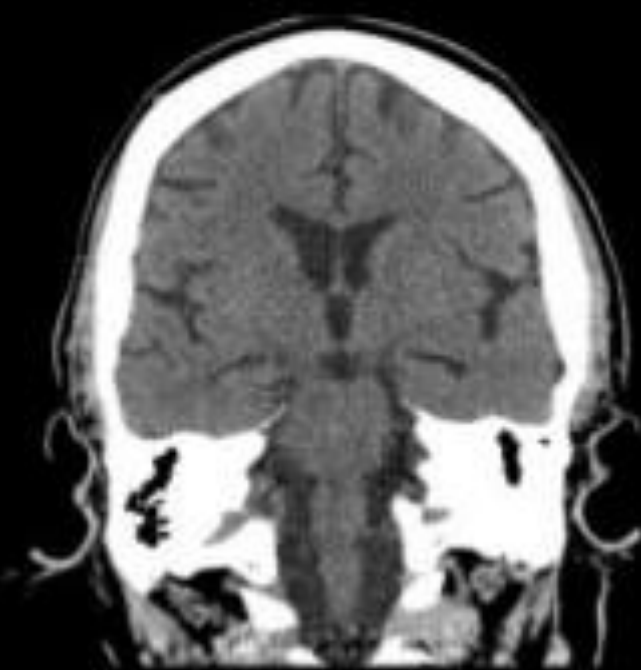why 3D



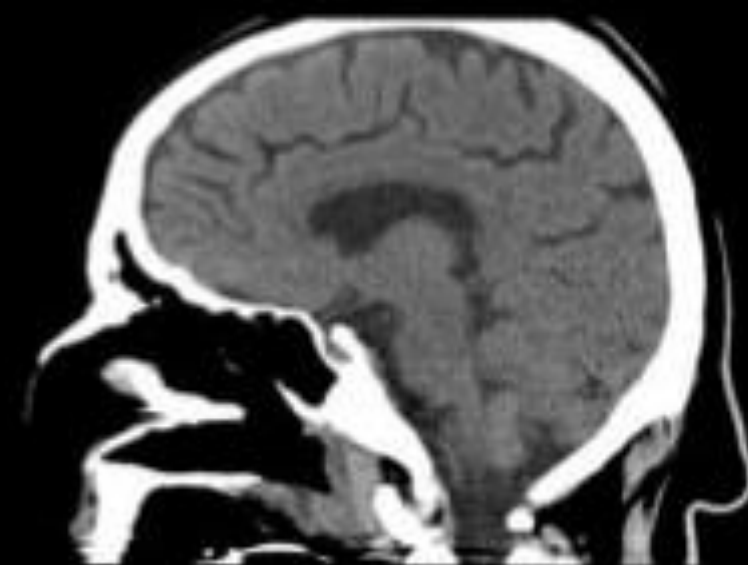




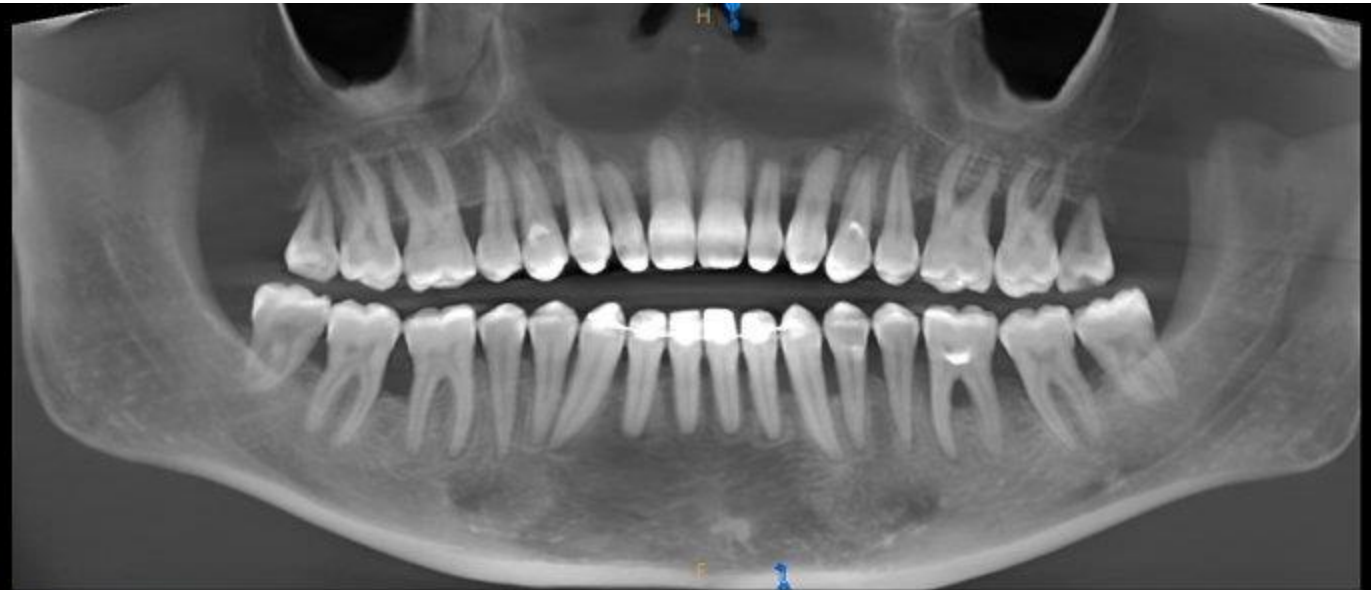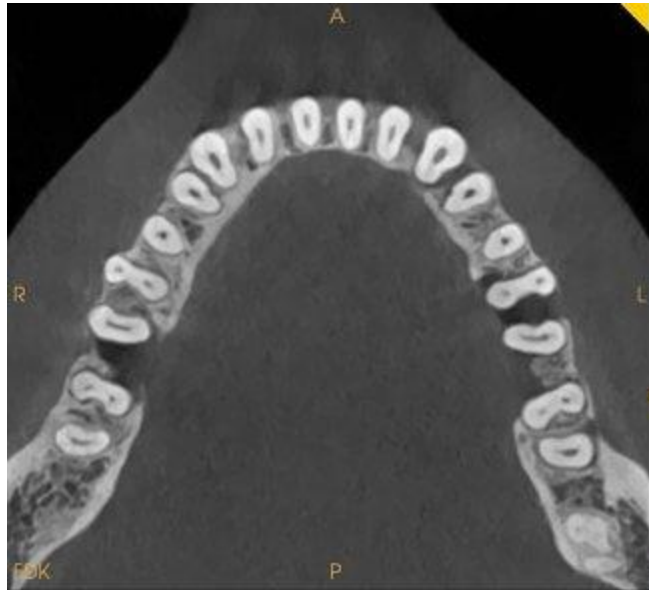
Axial plane



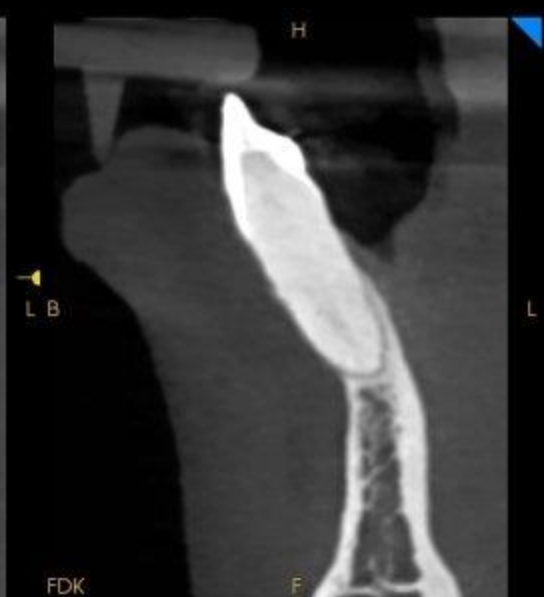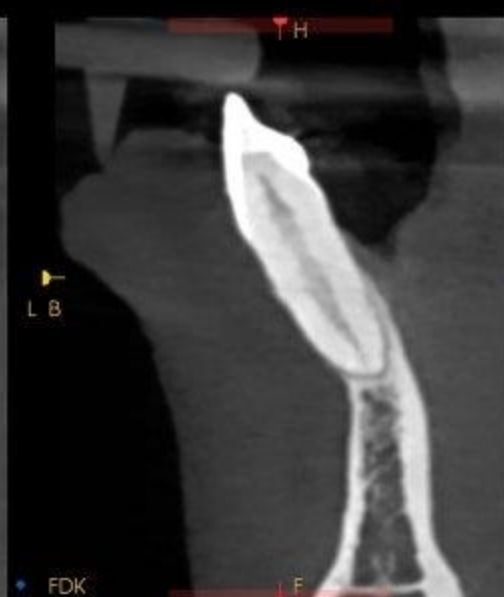
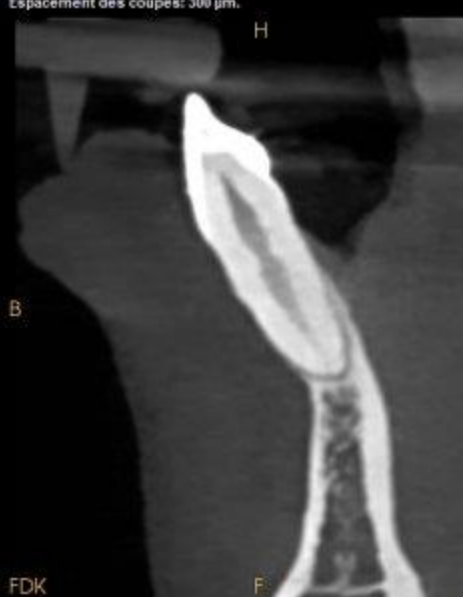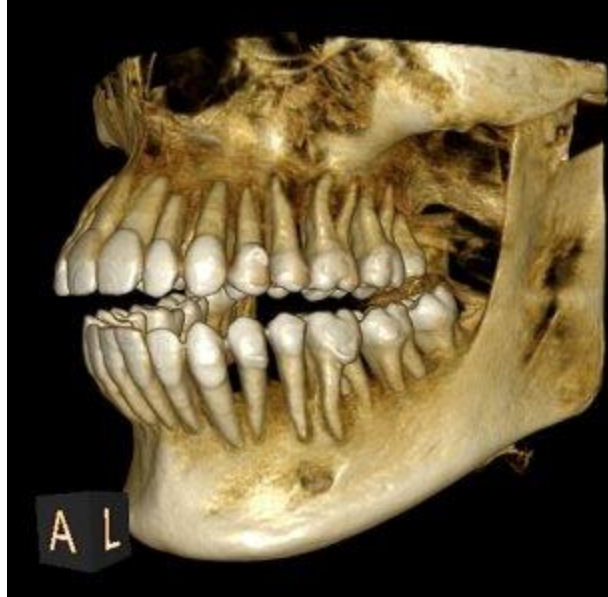Coronal plane



Sagittal plane



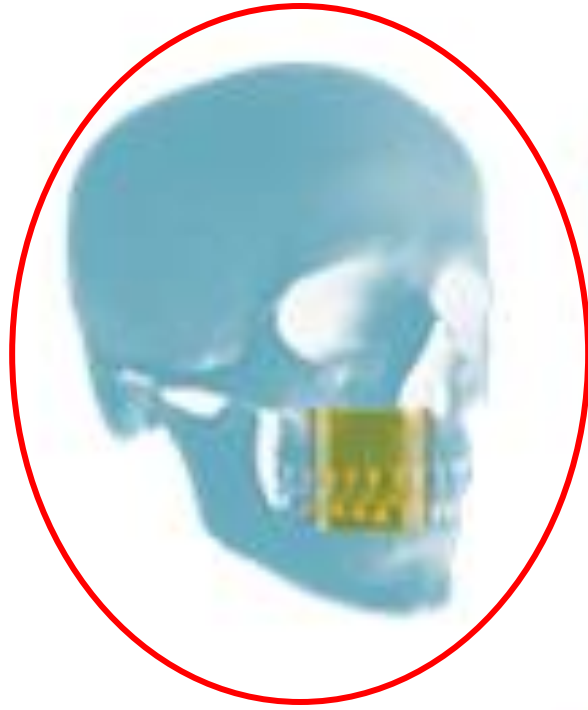Espacement des coupes: 300 µm.



Advantages of CBCT

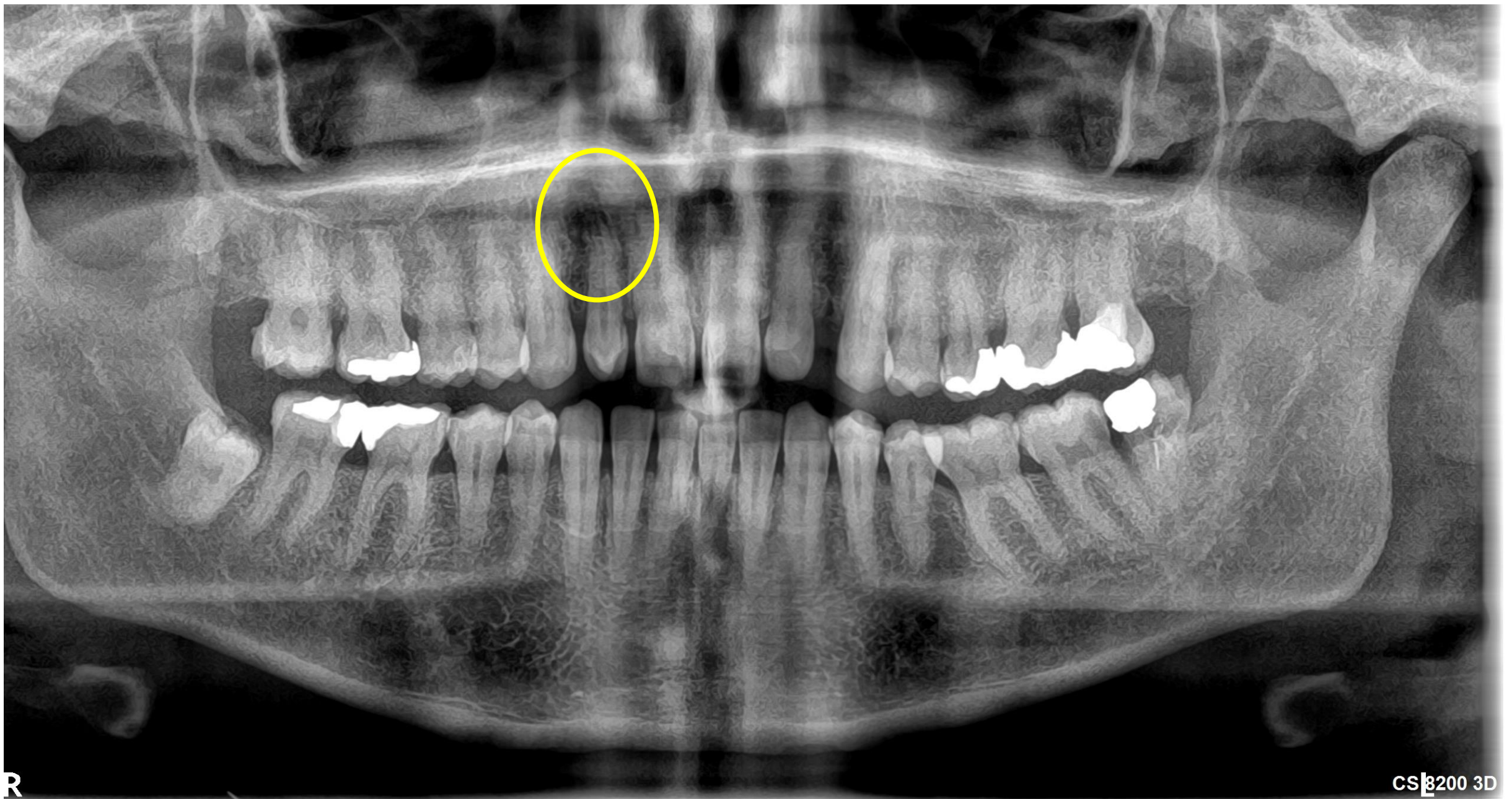
- 1- Rapid scan time
- 2- Beam limitation
- 3- Image accuracy
- 4- Reduction in radiation dose when compared with medical CT (10 times less)
- 5- Safe

Field of Vision



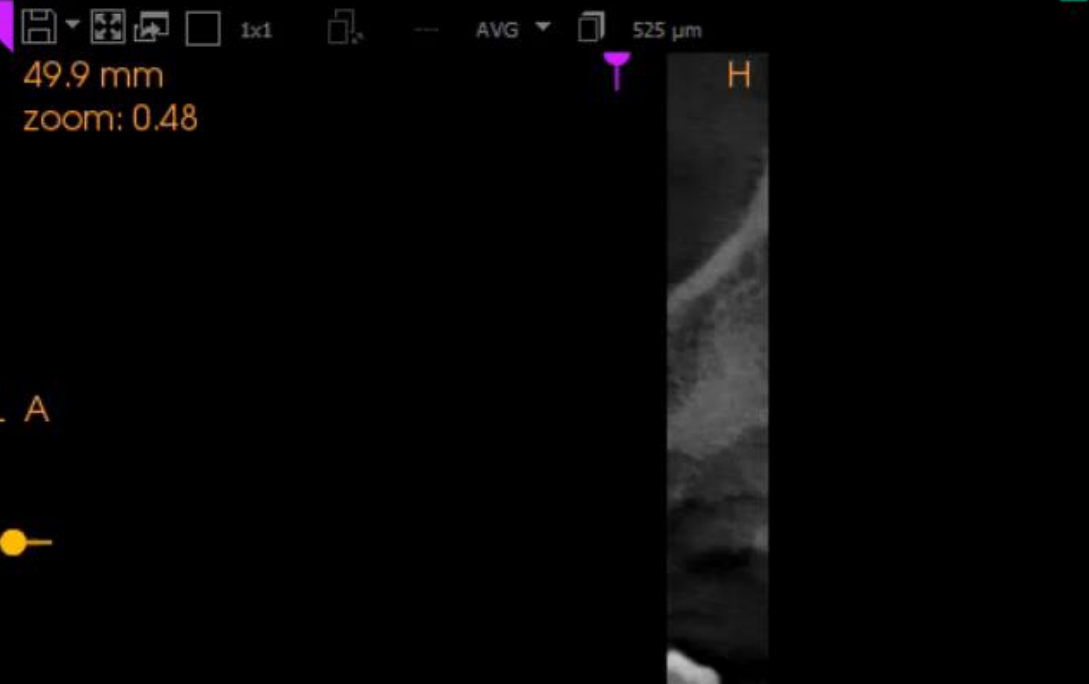
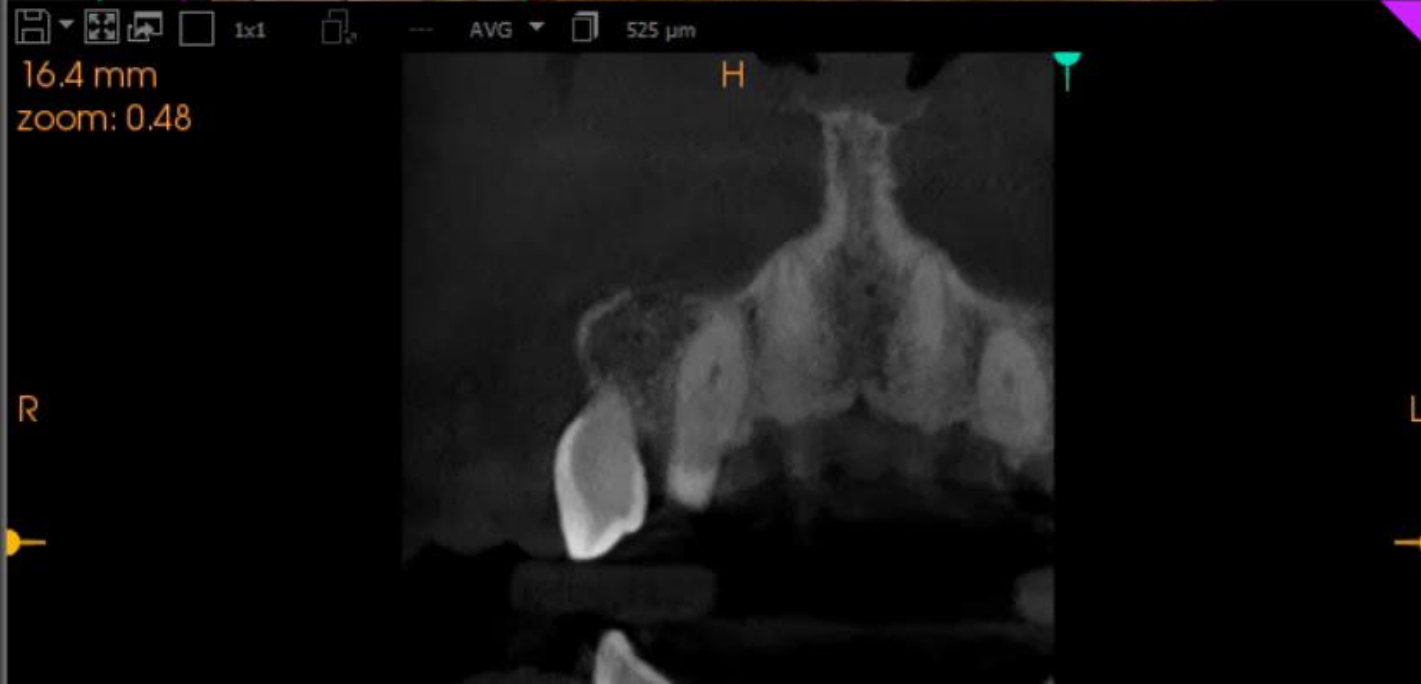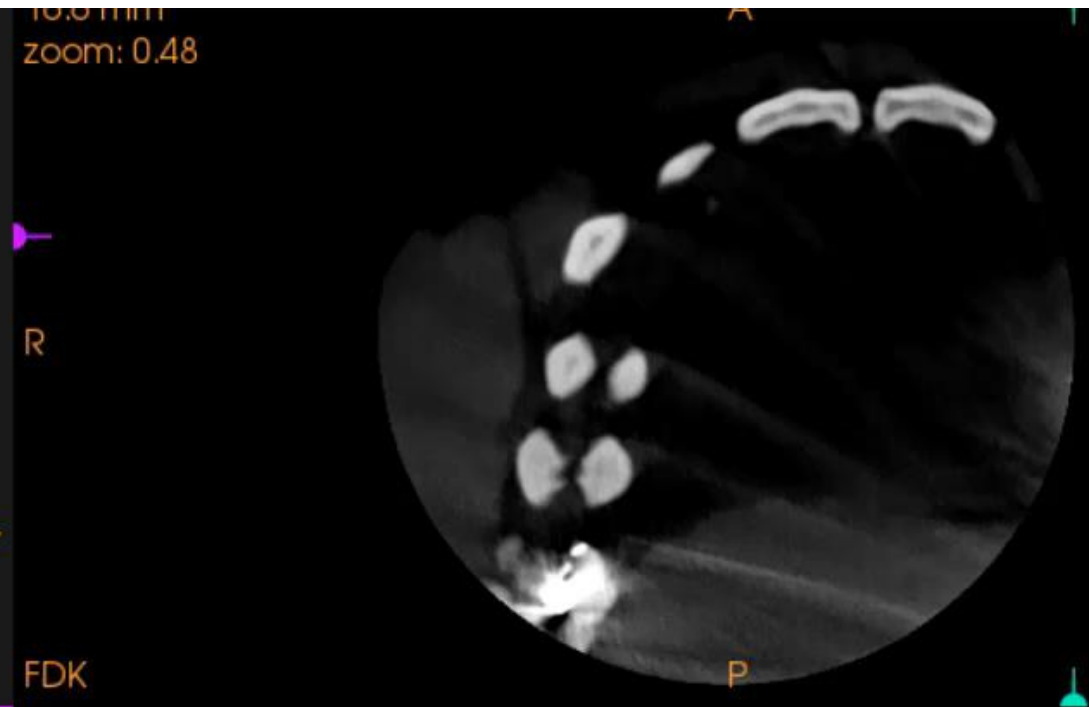
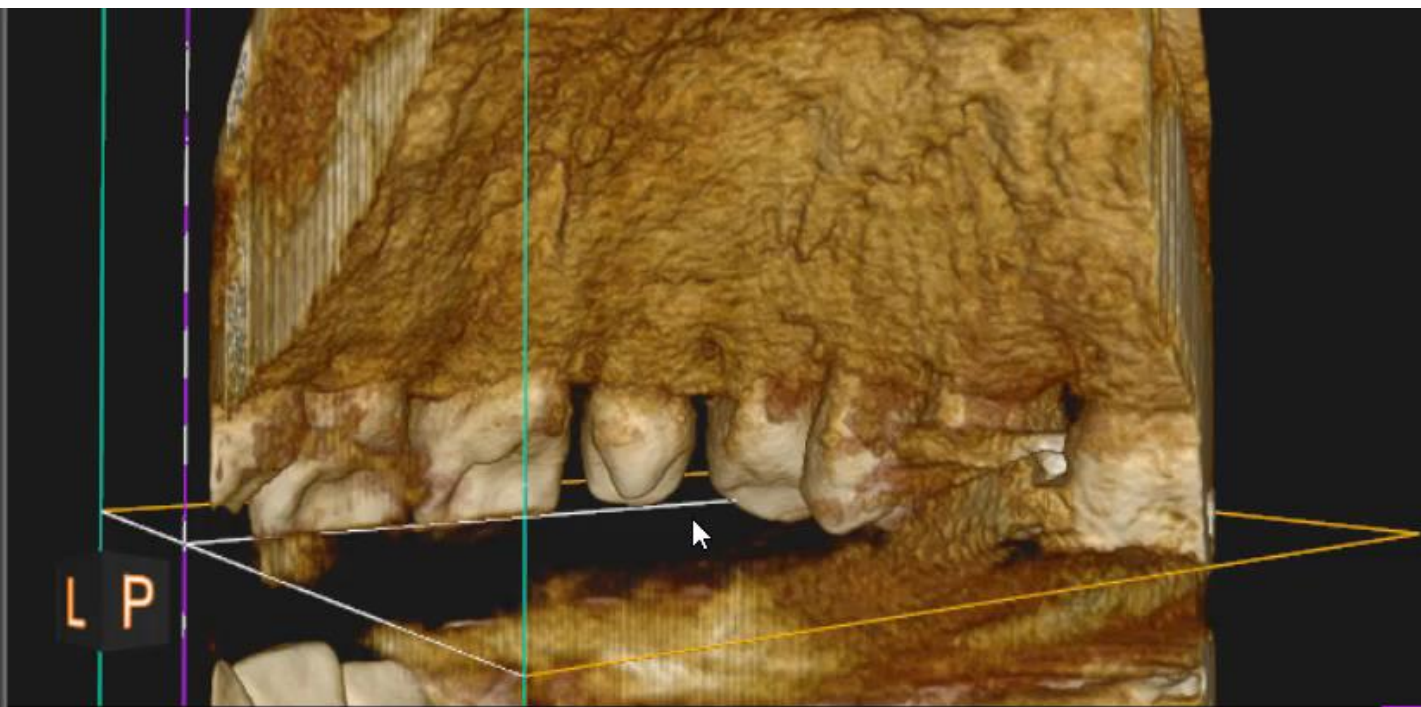


Diagnosis



R

CS 200 3D

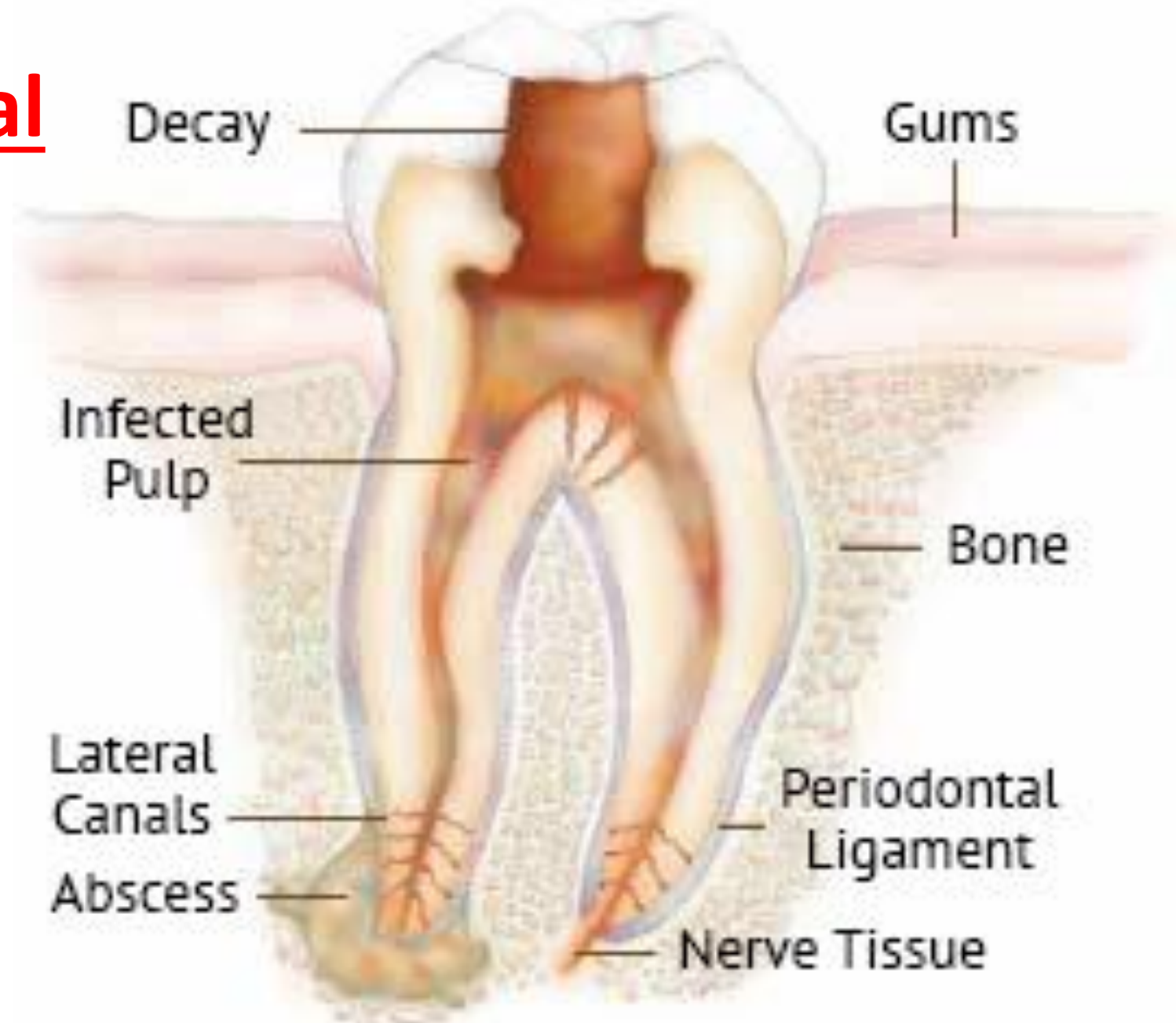


Lateral Canals

Prevalence of lateral canals

49% Huang et al 2018

45% Sousa et al 2010



Courtesy of Pacific Dental Care

Micro-computed tomographic assessment of the variability and morphological features of root canal system and their ramifications

[Jardel Francisco MAZZI-CHAVES](#),^{1,2} [Yara Terezinha Corrêa SILVA-SOUSA](#),³ [Graziela Bianchi LEONI](#),³
[Alice Corrêa SILVA-SOUSA](#),³ [Lucas ESTRELA](#),⁴ [Carlos ESTRELA](#),⁴ [Reinhilde JACOBS](#),² and
[Manoel Damião de SOUSA-NETO](#)¹

Mandibular first premolars (85%)

first and second molars (84%)

lateral incisors (67%)

canines (59%)

maxillary first premolars (52%)

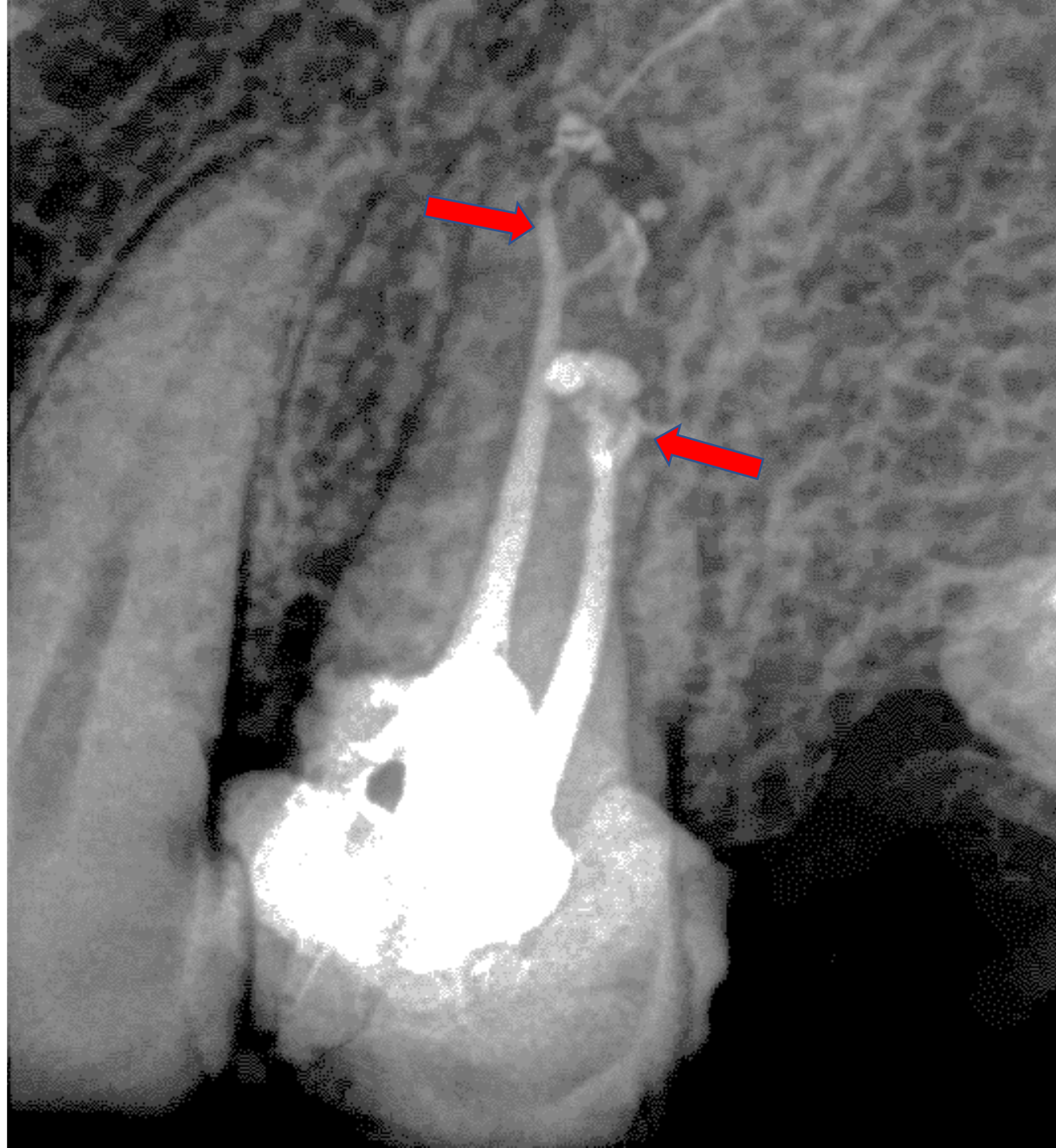
➤ [BMC Oral Health. 2017 Nov 29;17\(1\):142. doi: 10.1186/s12903-017-0430-1.](#)

Could cone-beam computed tomography demonstrate the lateral accessory canals?

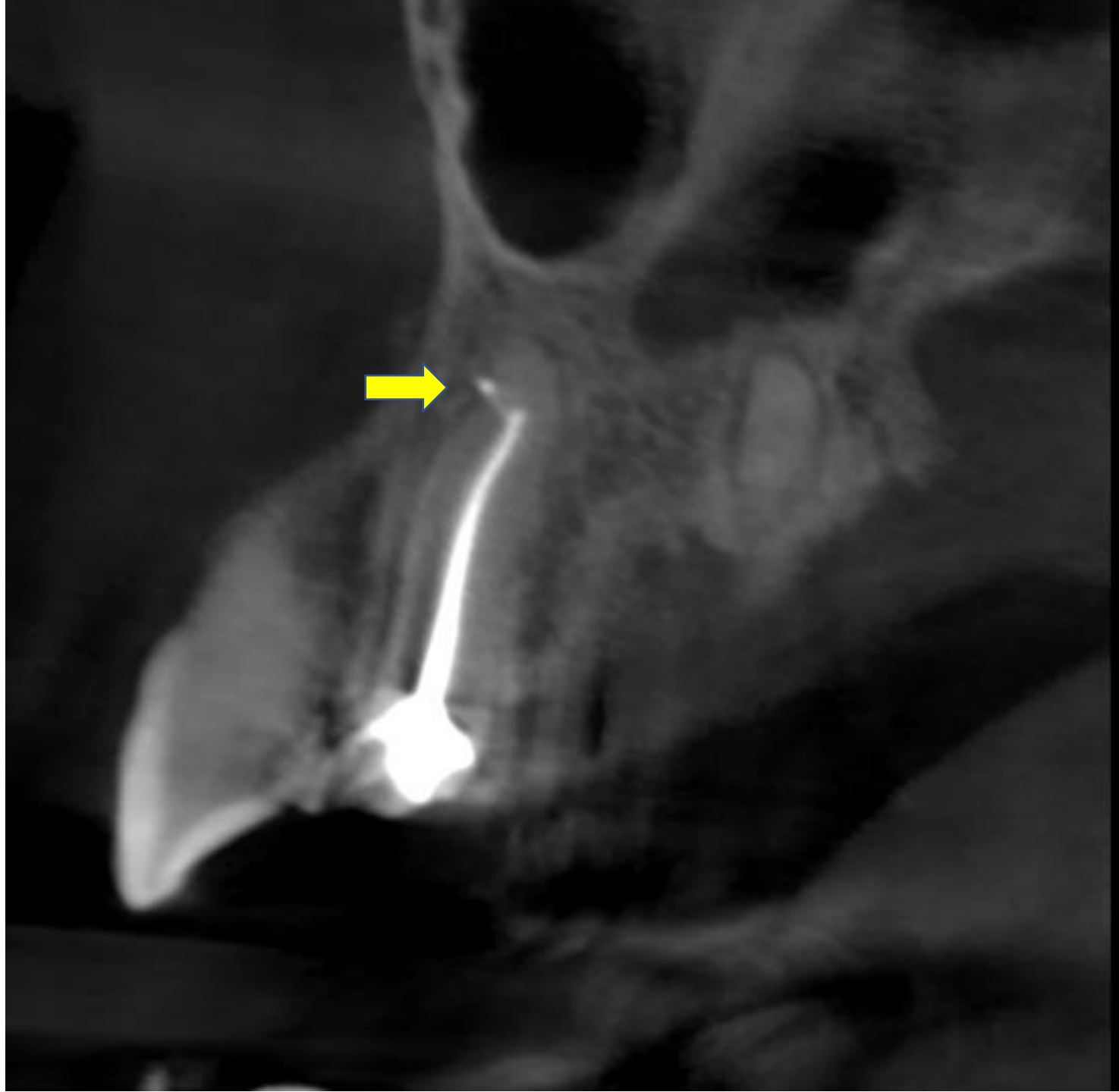
Yan Ji ¹, Shanhui Wen ², Shu Liu ², Min Zhu ³, Menghuan Yao ², Tiemei Wang ⁴, Zitong Lin ⁵

The HZ mode should be chosen to demonstrate the root canal system, and partial LACs.

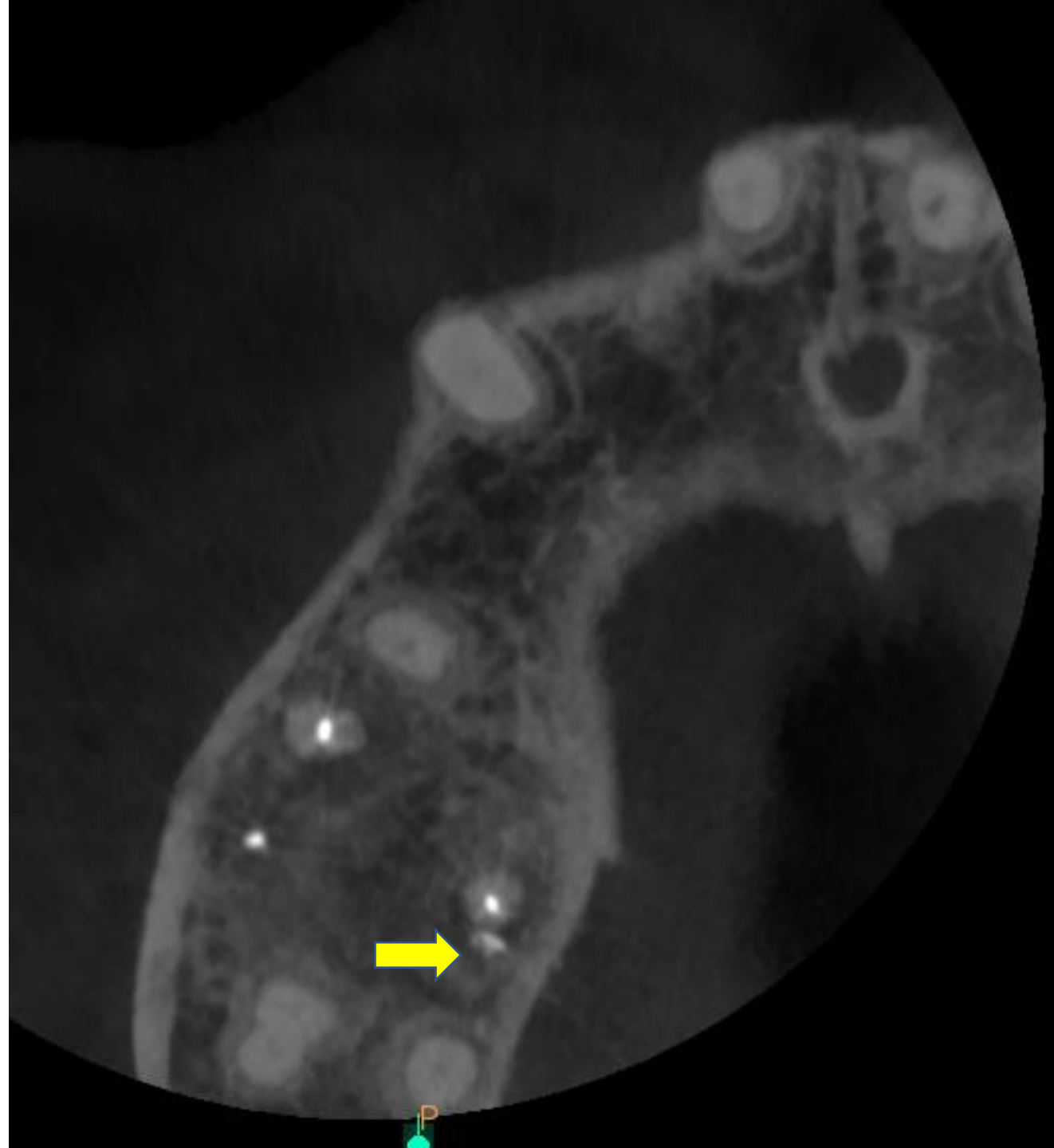Apical
deltas

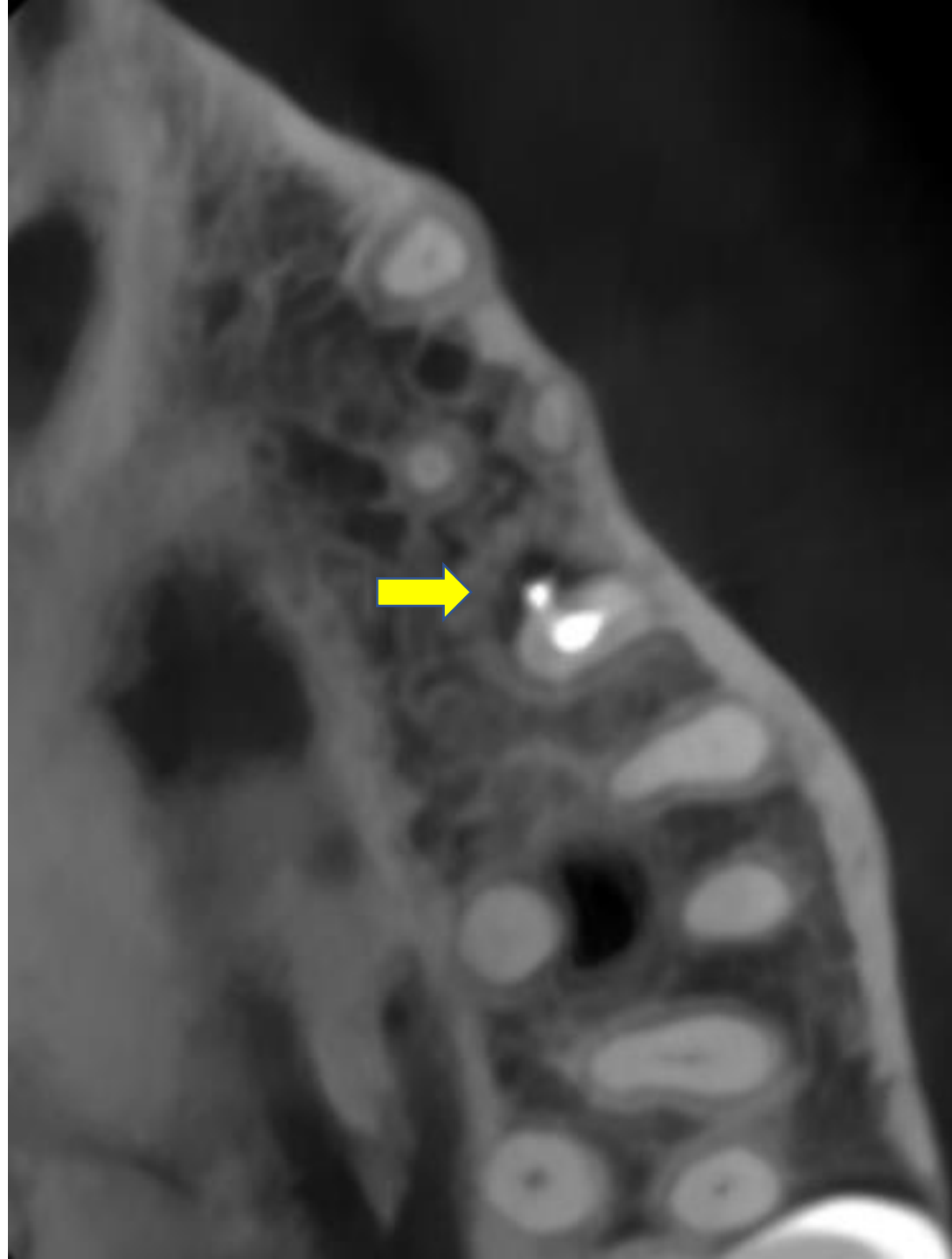
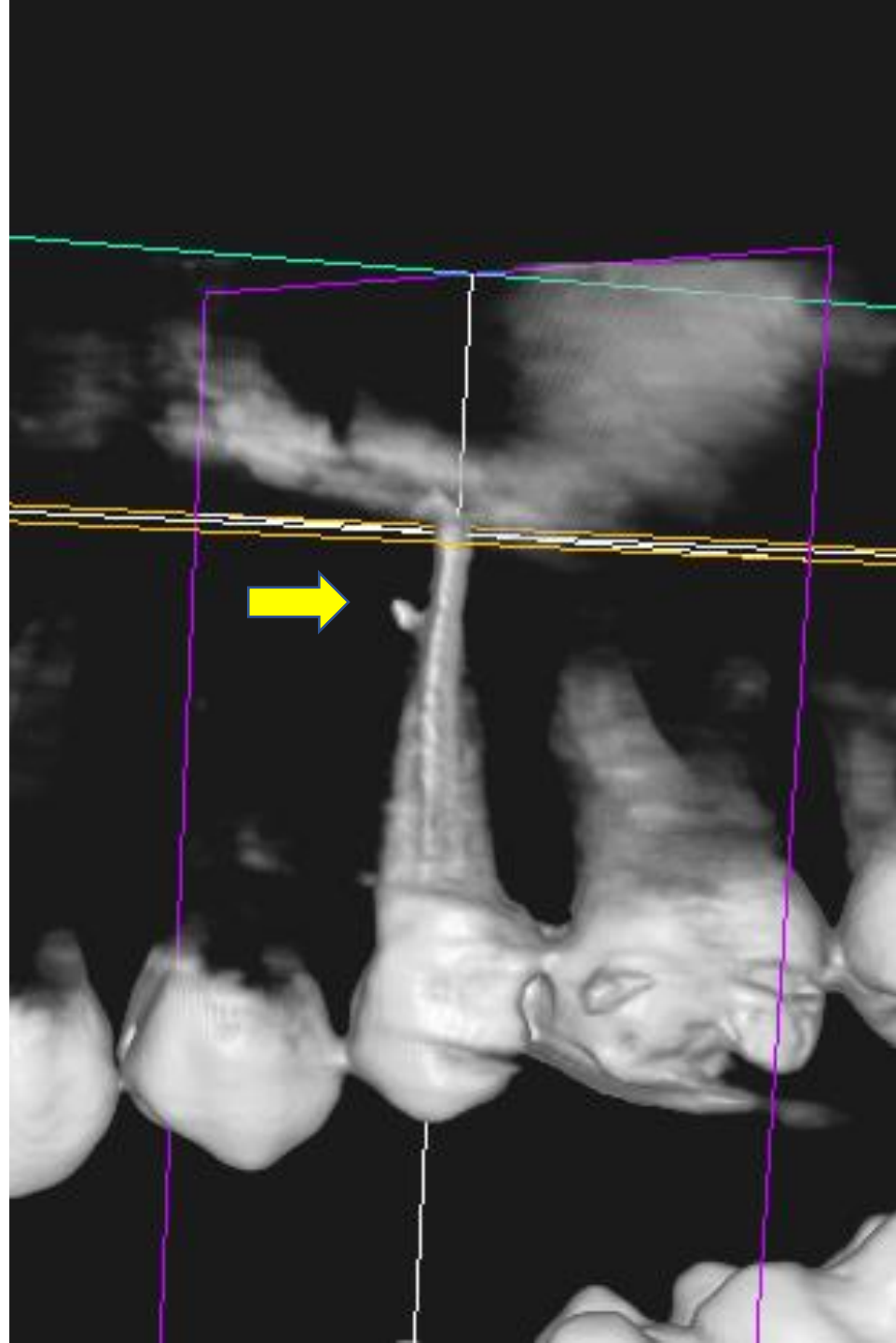


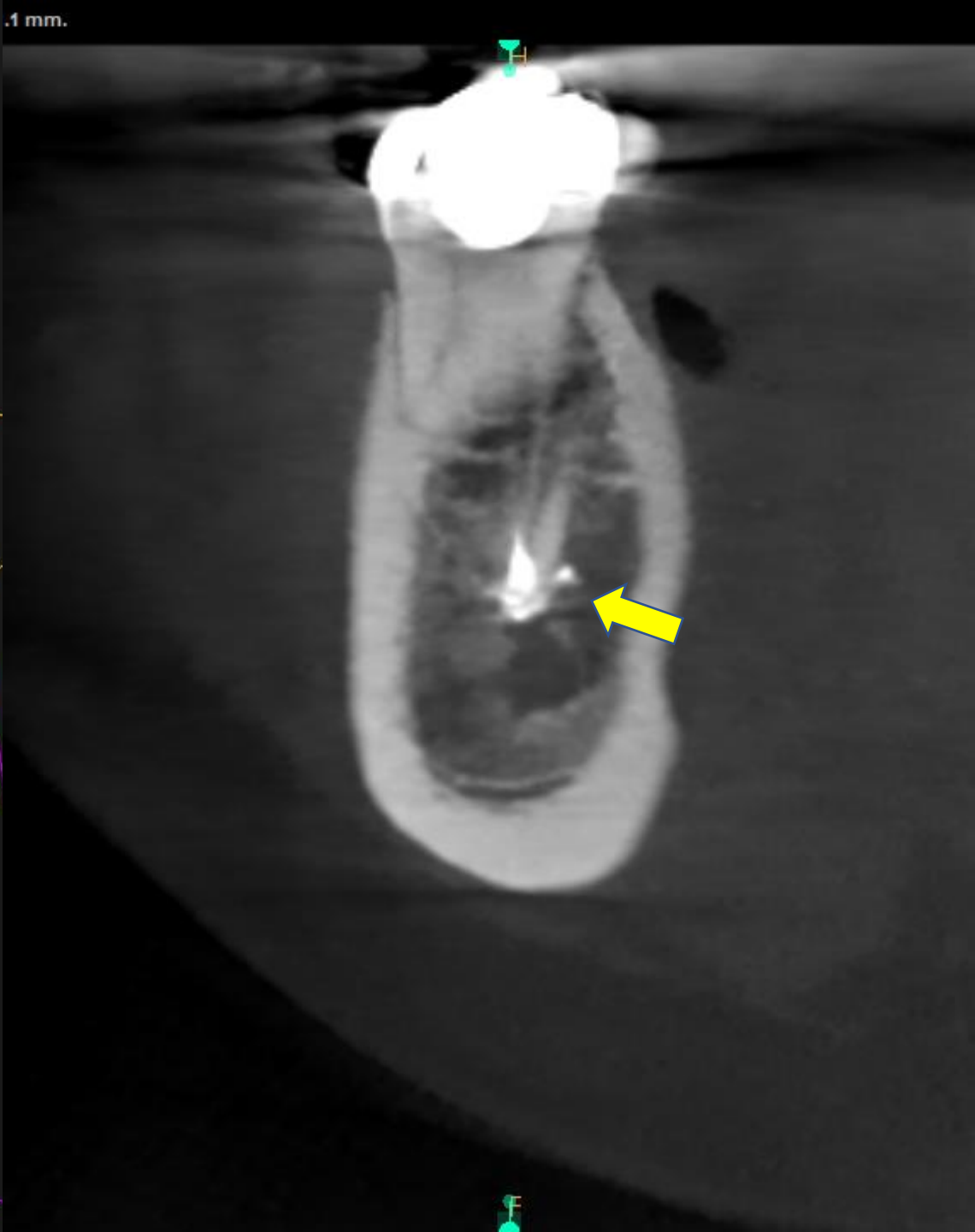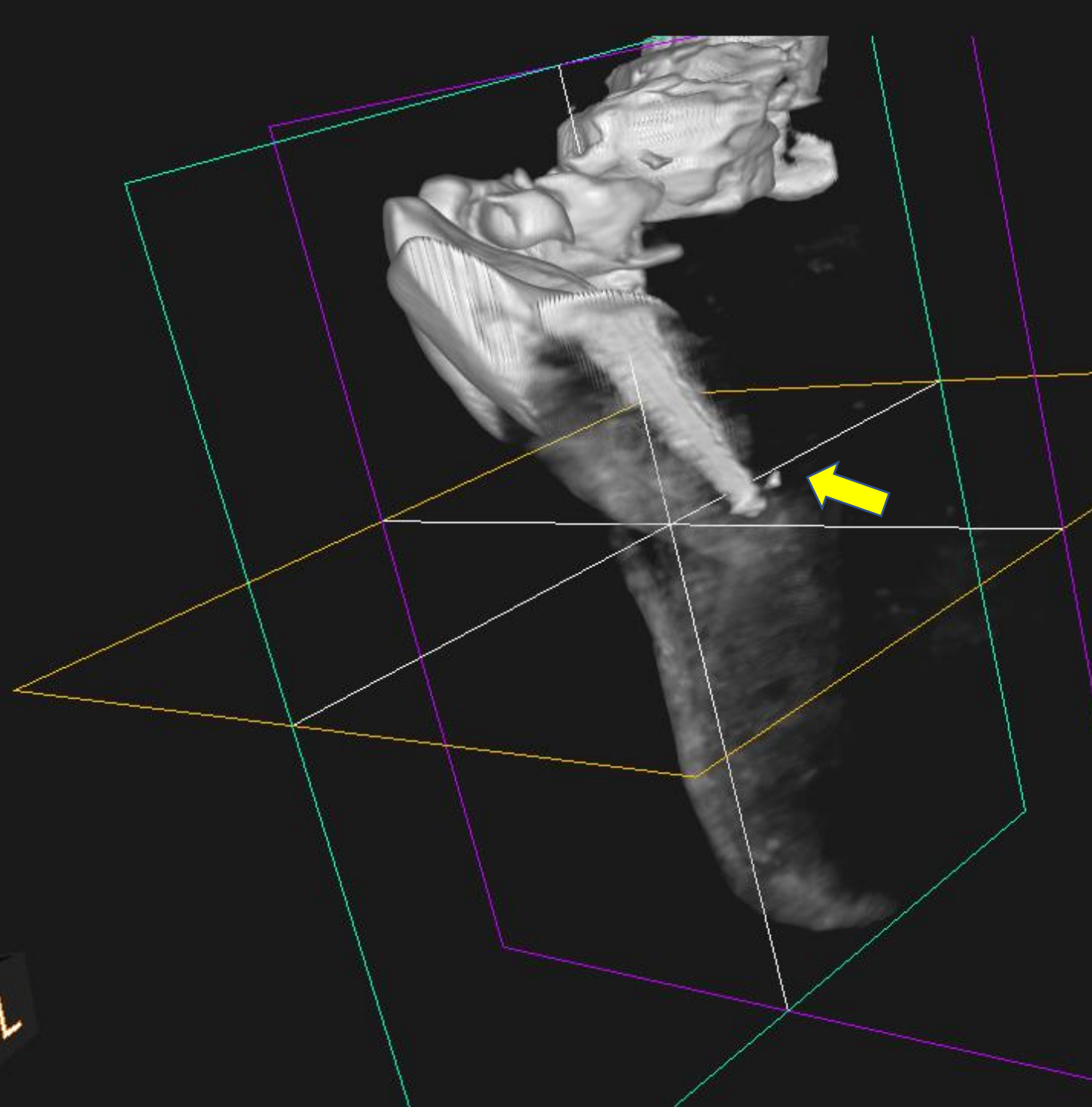
**Extrusion of lateral
canal labially**

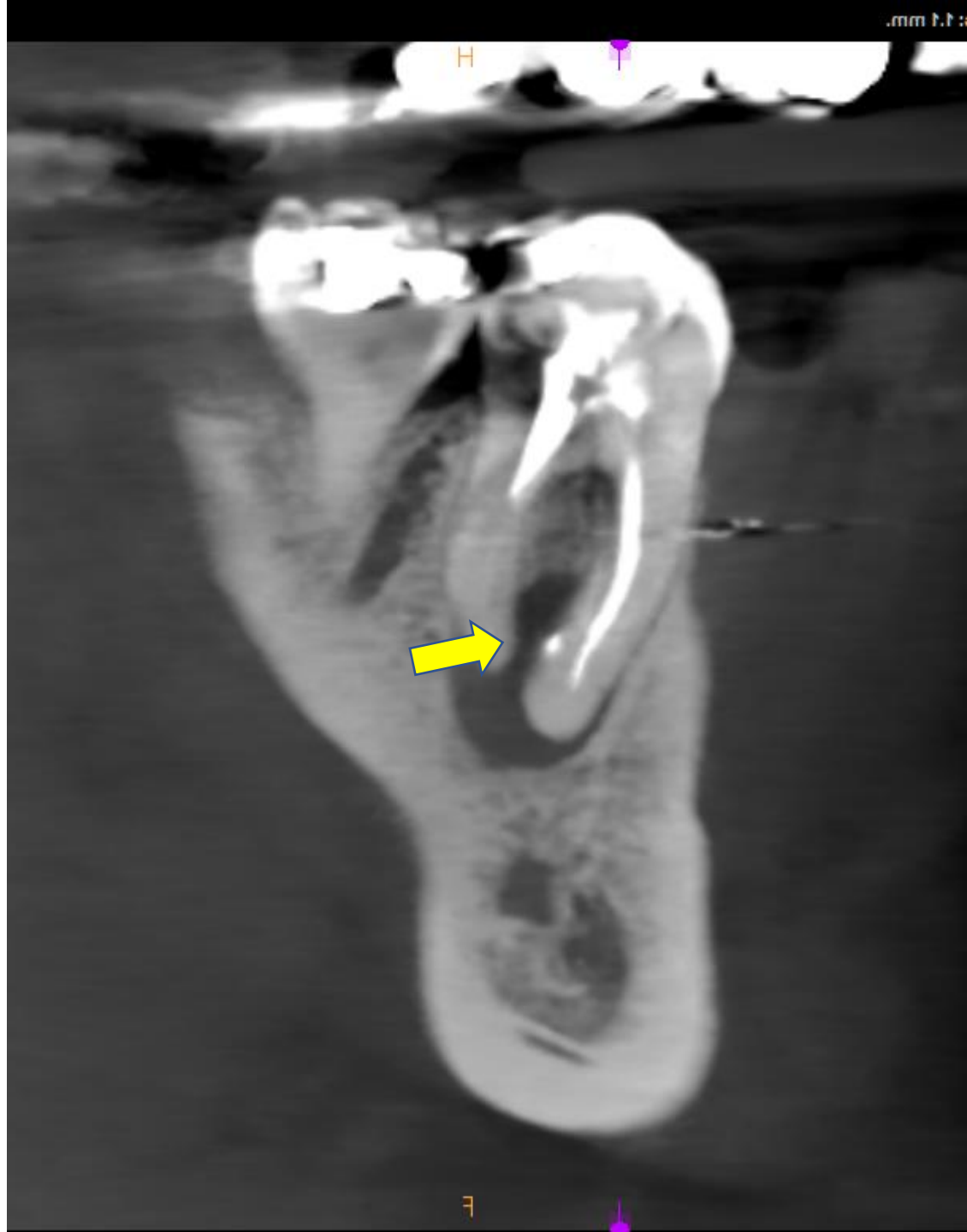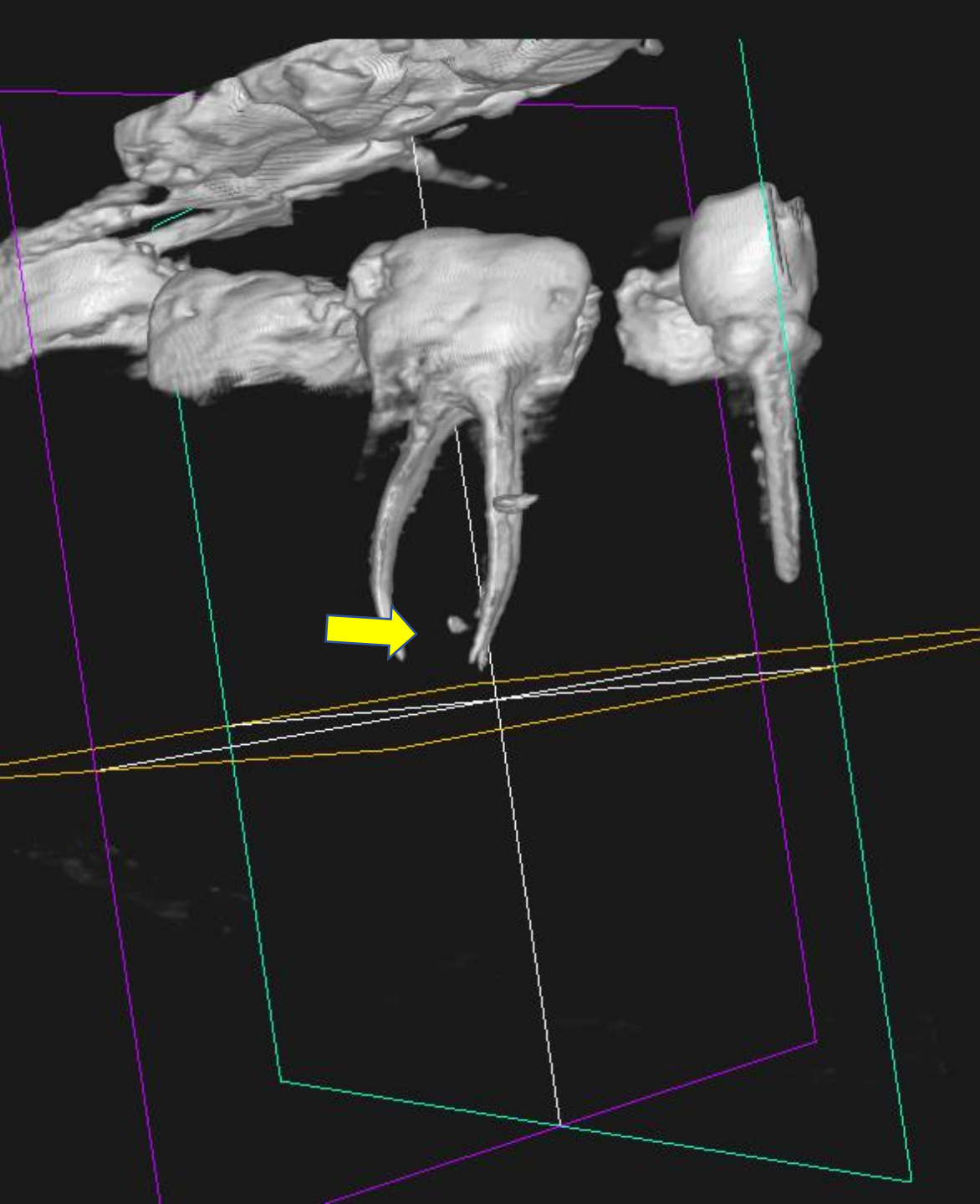


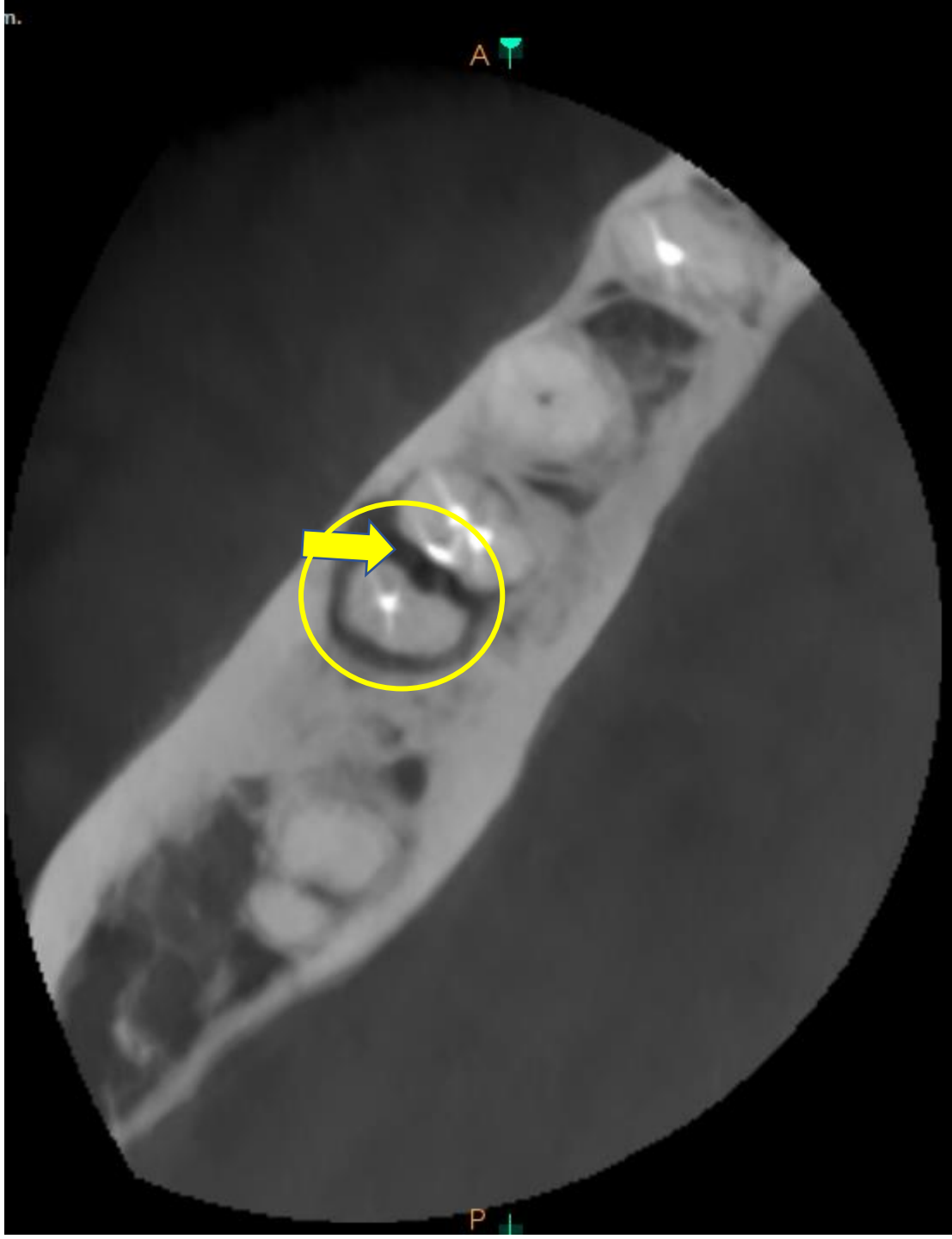Extrusion of lateral canal palatally





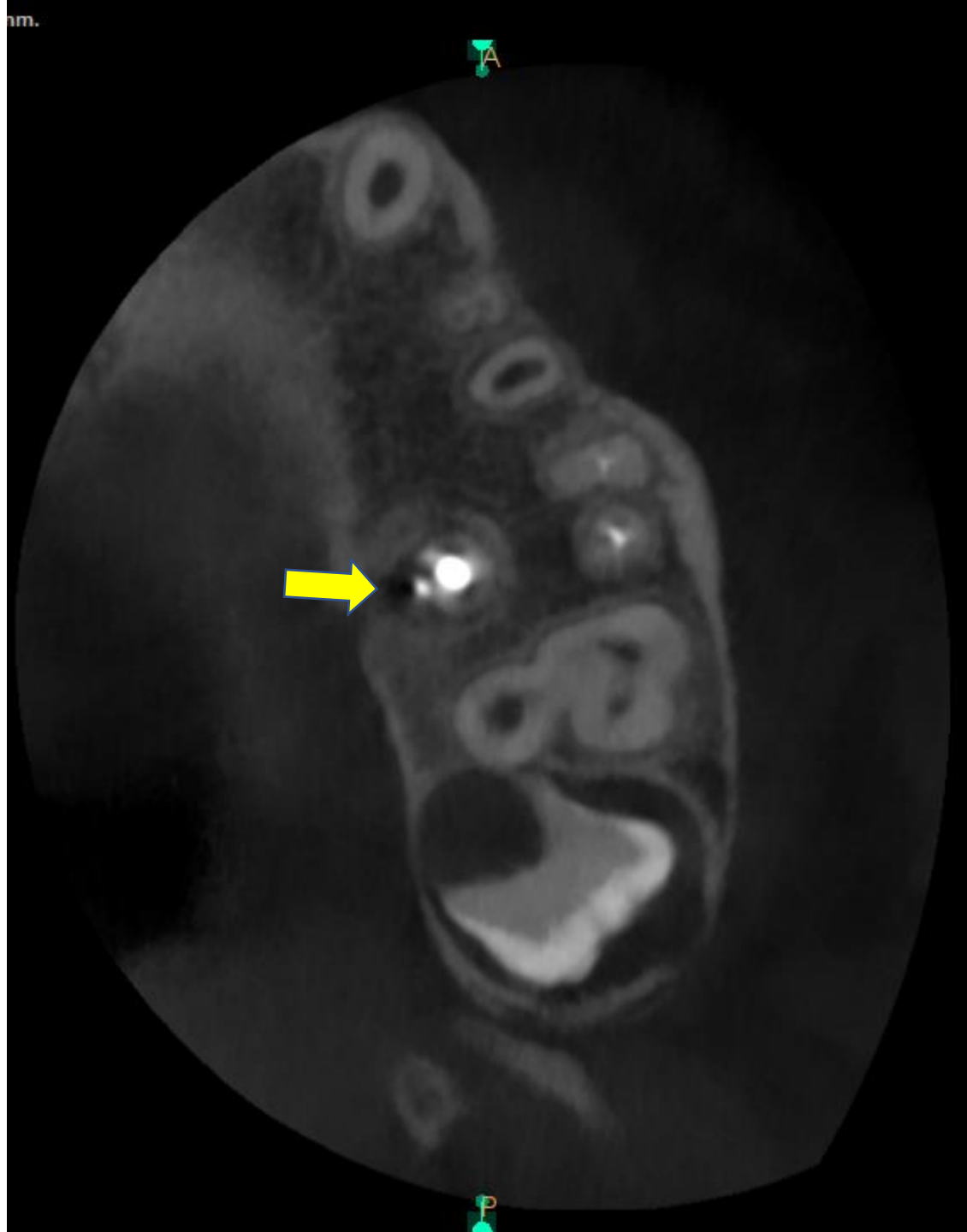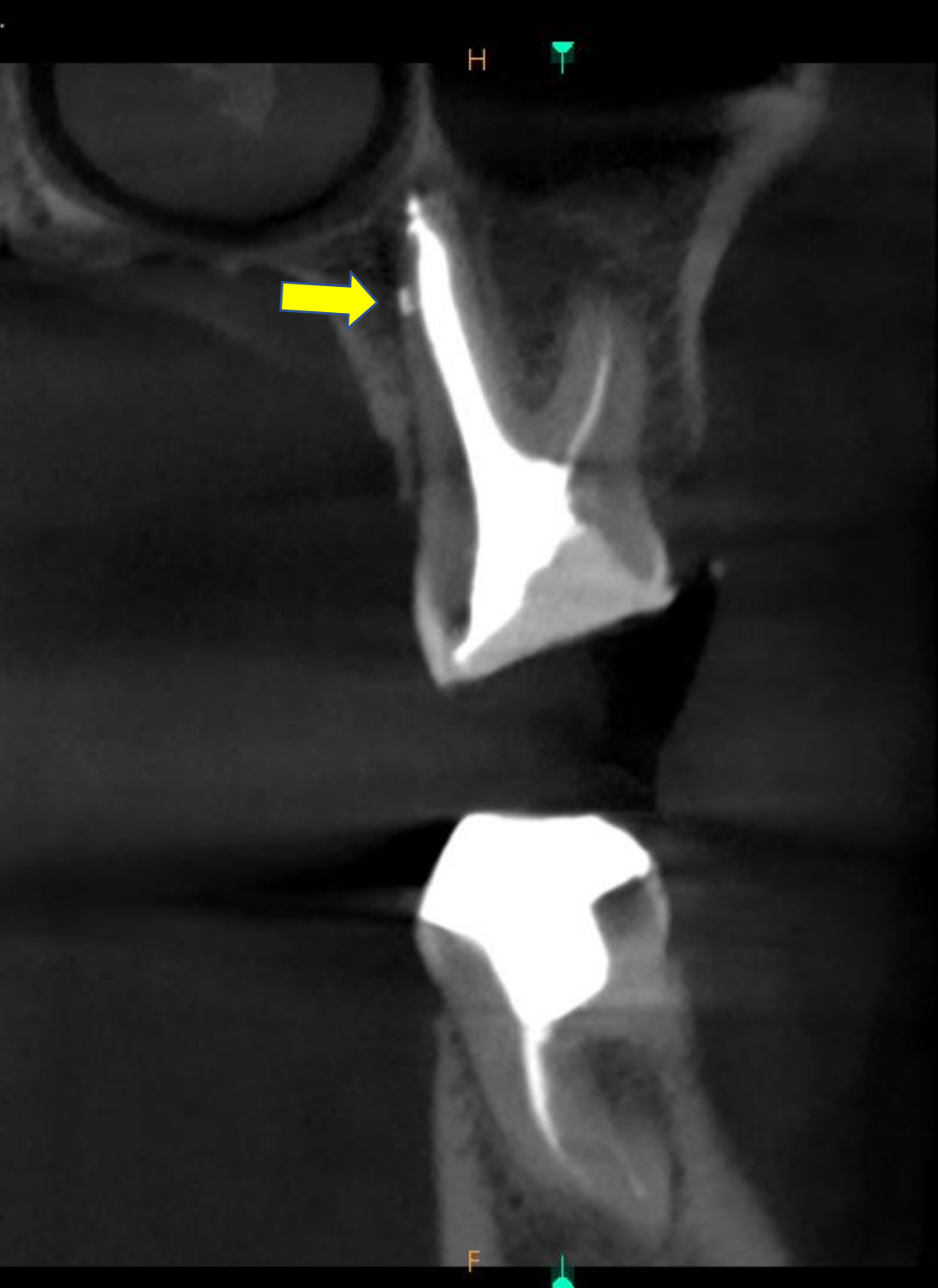






A

P



Extensive Lesions

› Eur Endod J. 2021 Apr;6(1):56-71. doi: 10.14744/eej.2021.29981. Epub 2021 Mar 23.

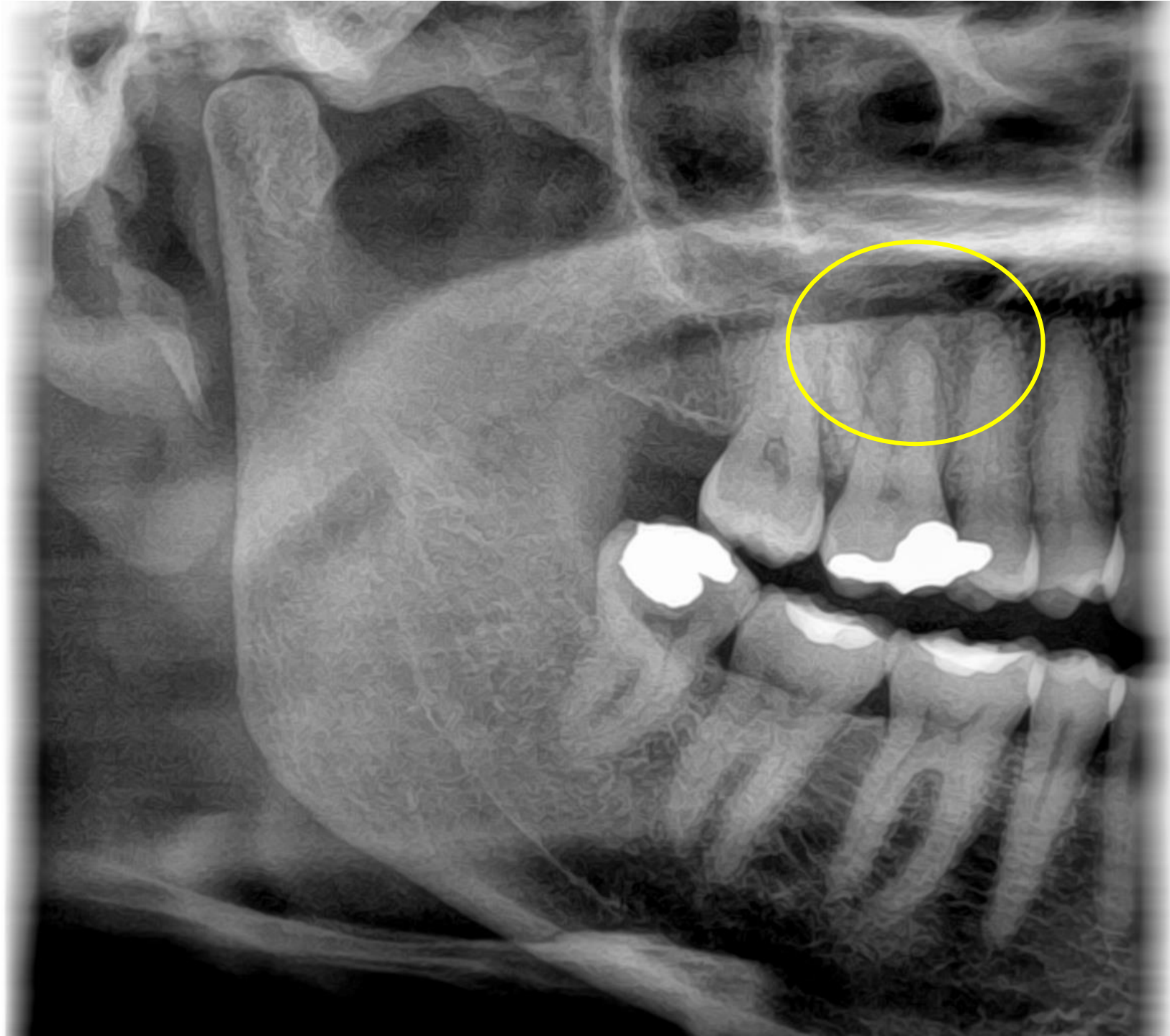
Prevalence of Lateral Radiolucency, Apical Root Resorption and Periapical Lesions in Portuguese Patients: A CBCT Cross-Sectional Study with a Worldwide Overview

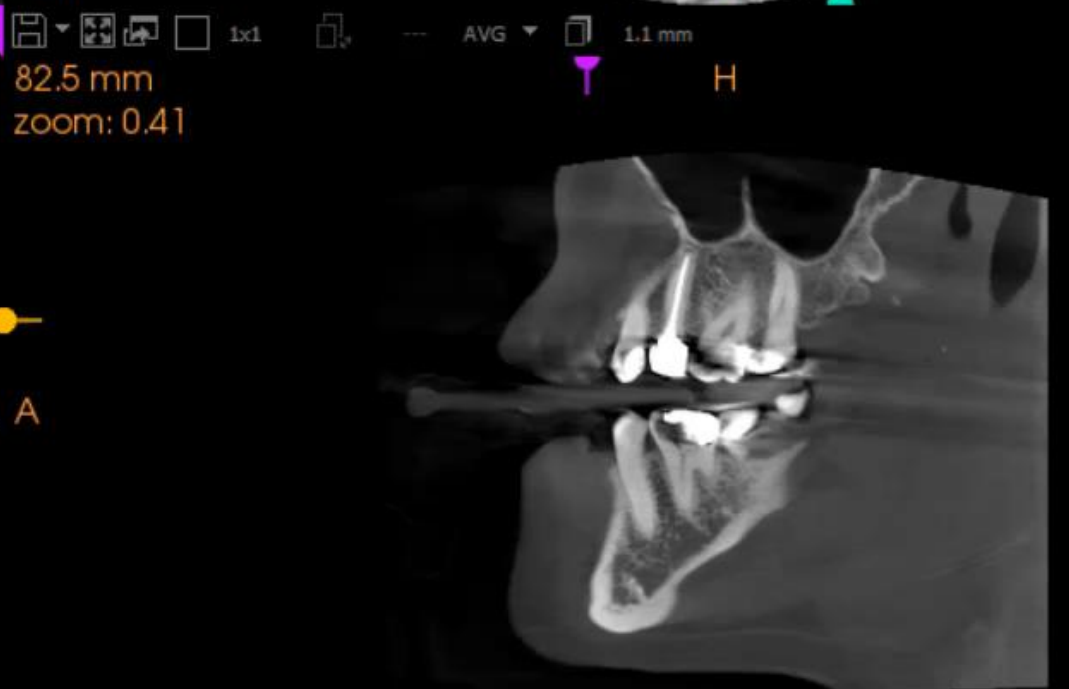
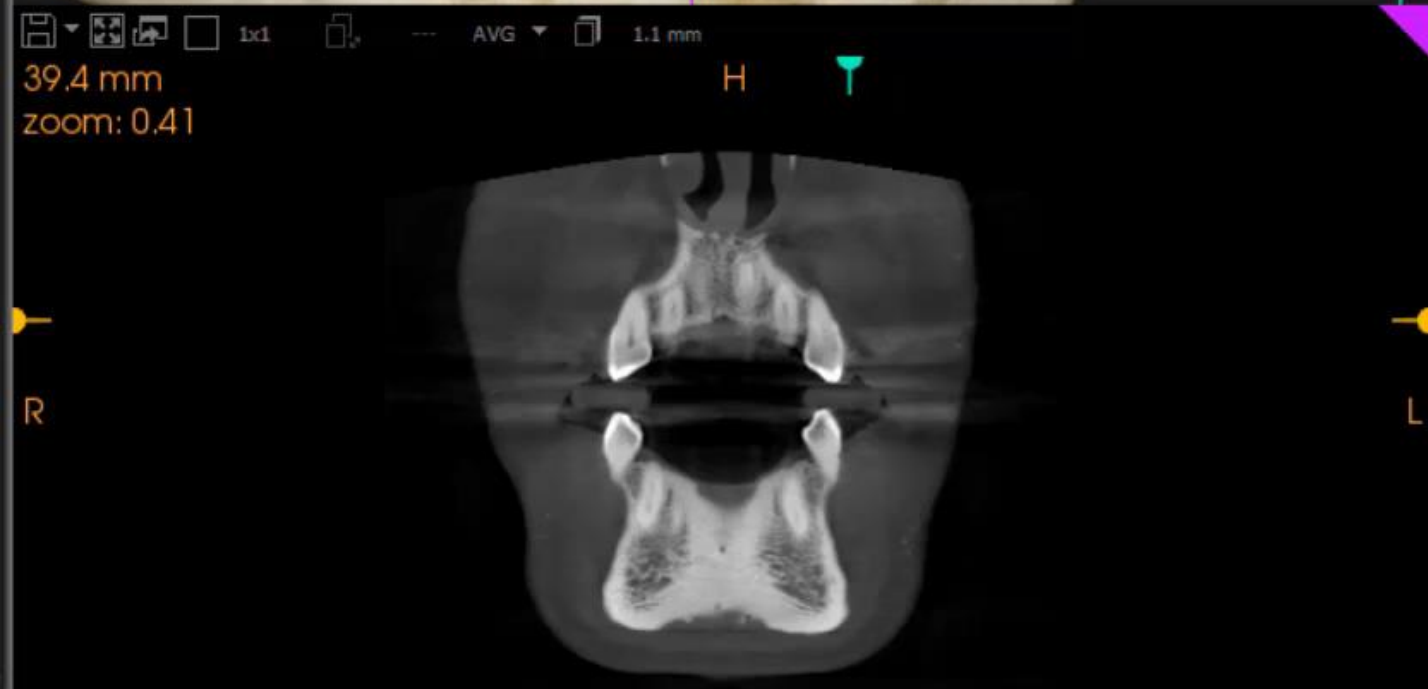
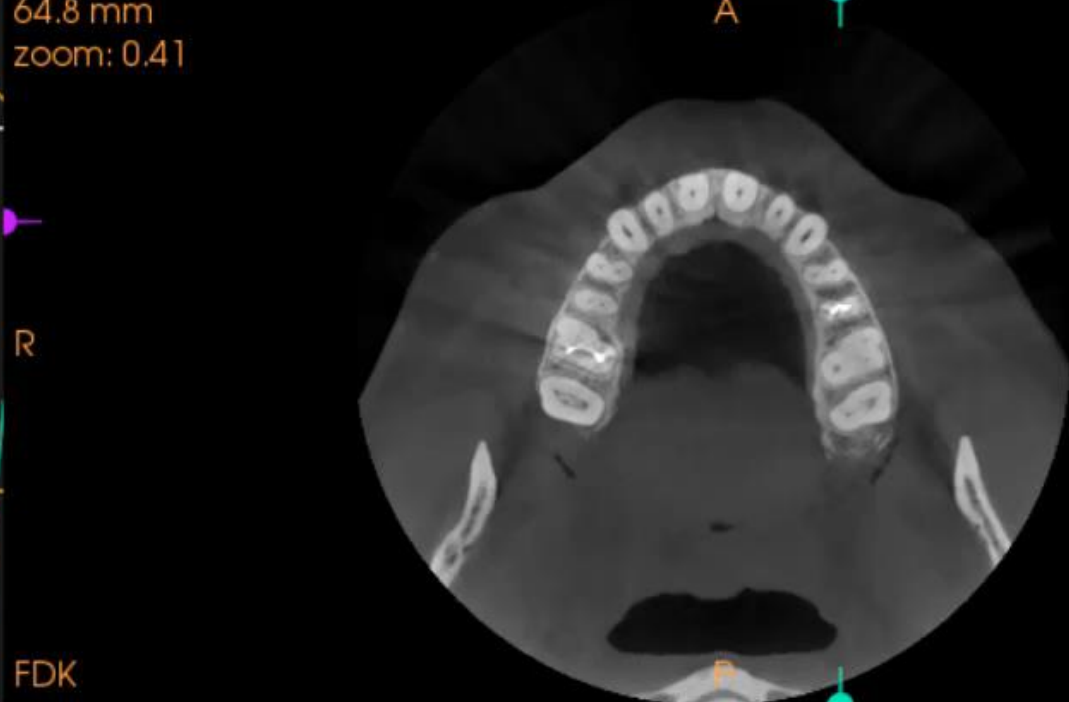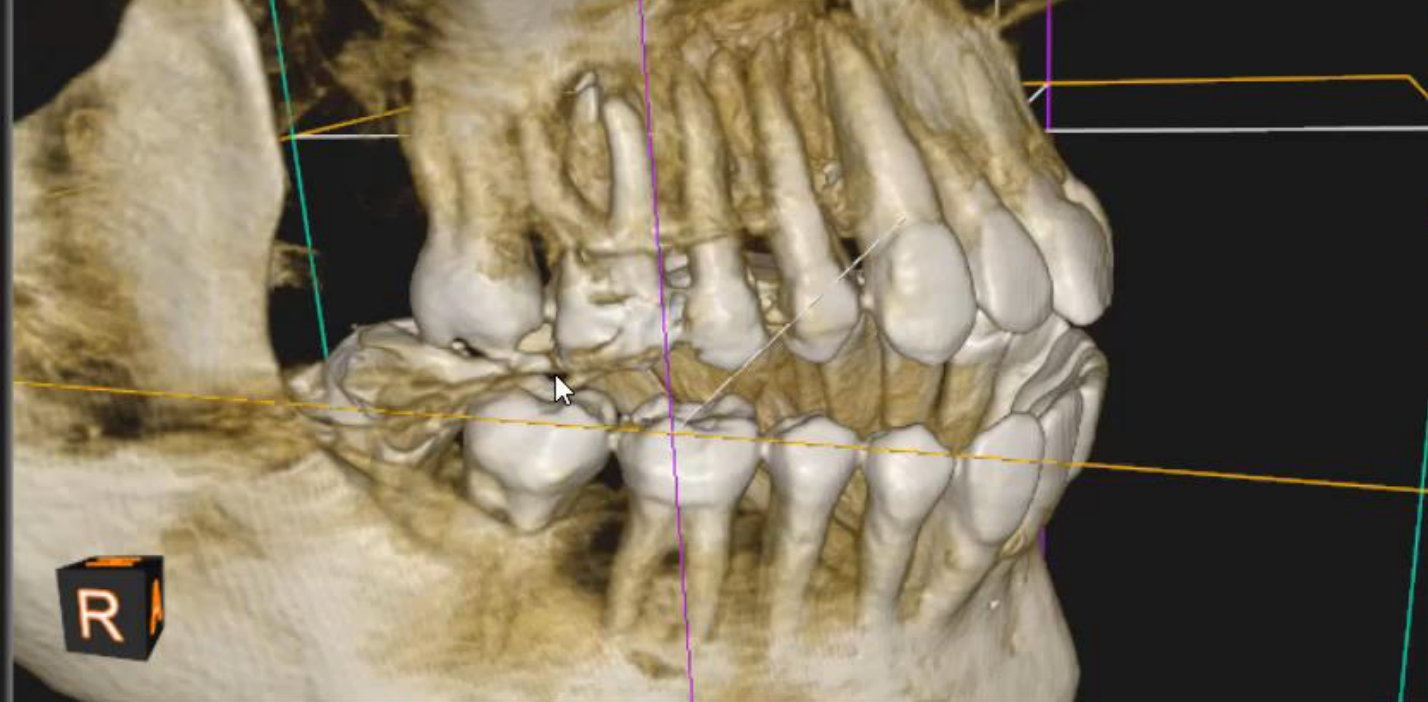João Meirinhos ¹, Jorge Martins ¹, Beatriz Pereira ², Abayomi Baruwa ², António Ginjeira ¹

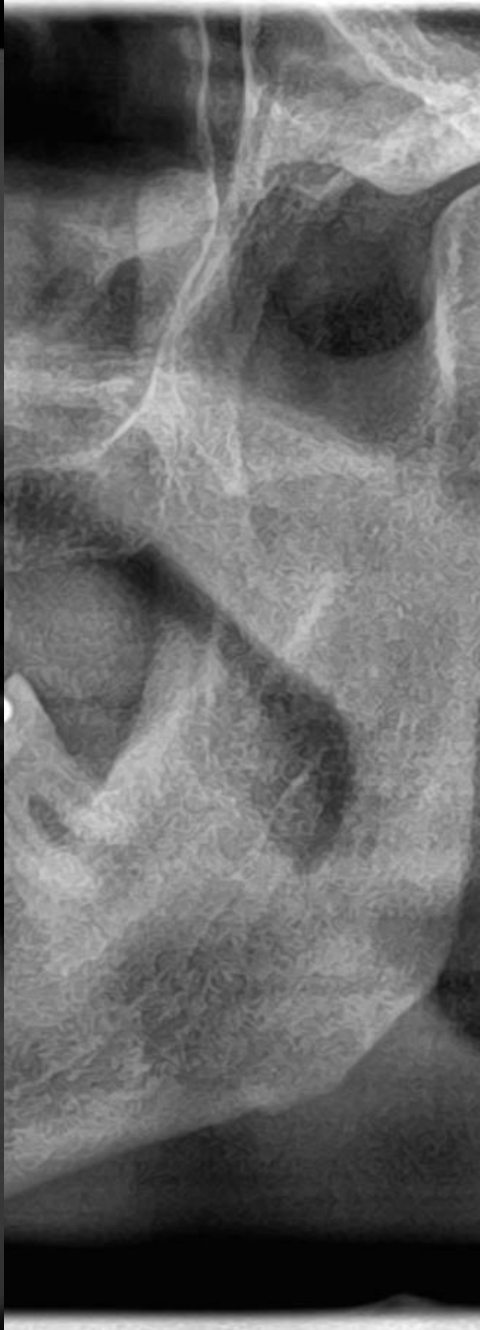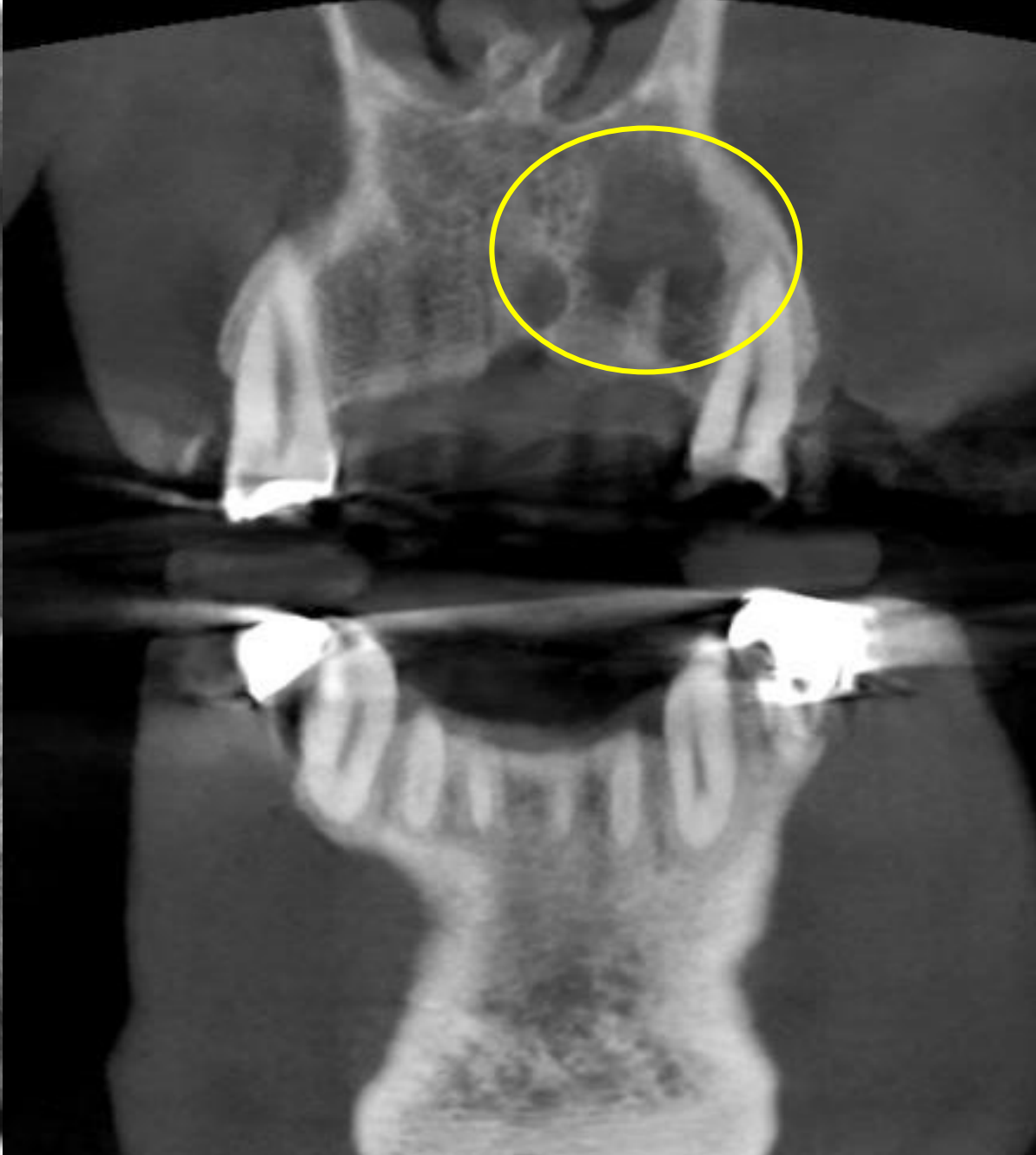
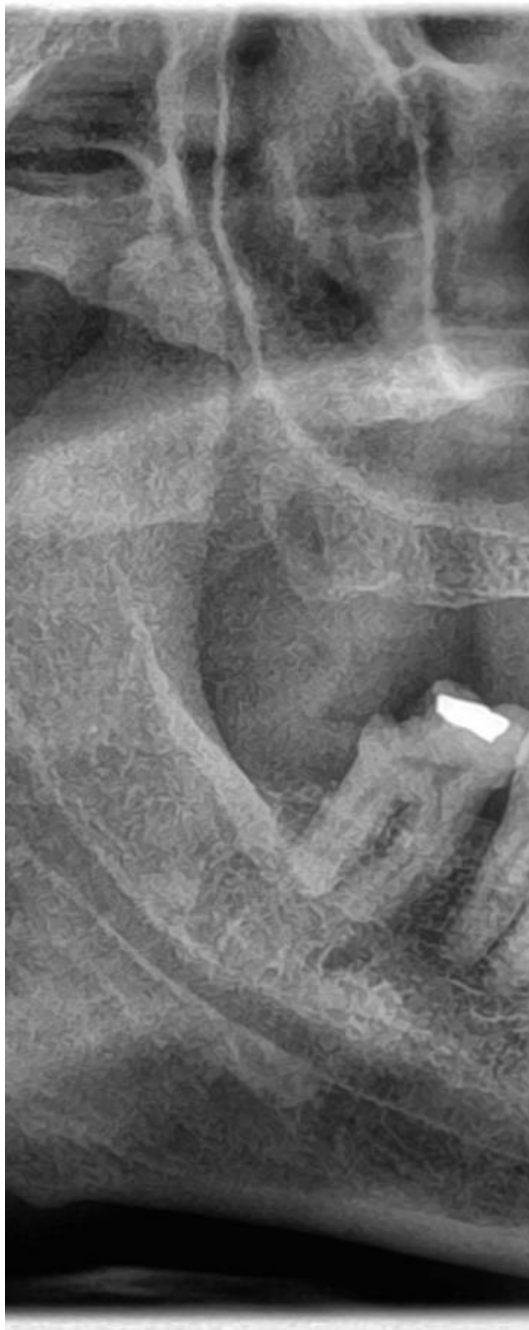Lateral lesions 0-0.9%

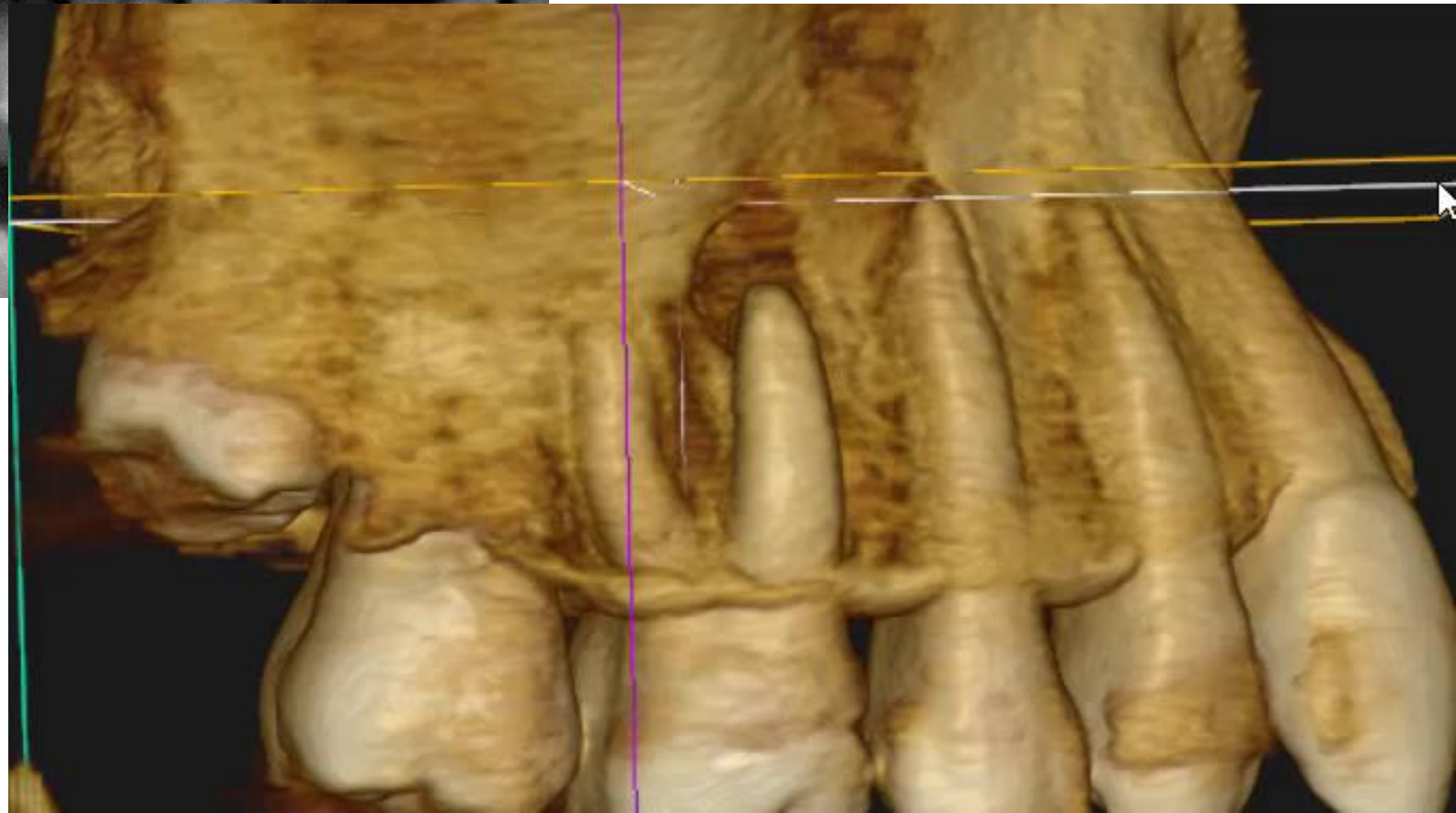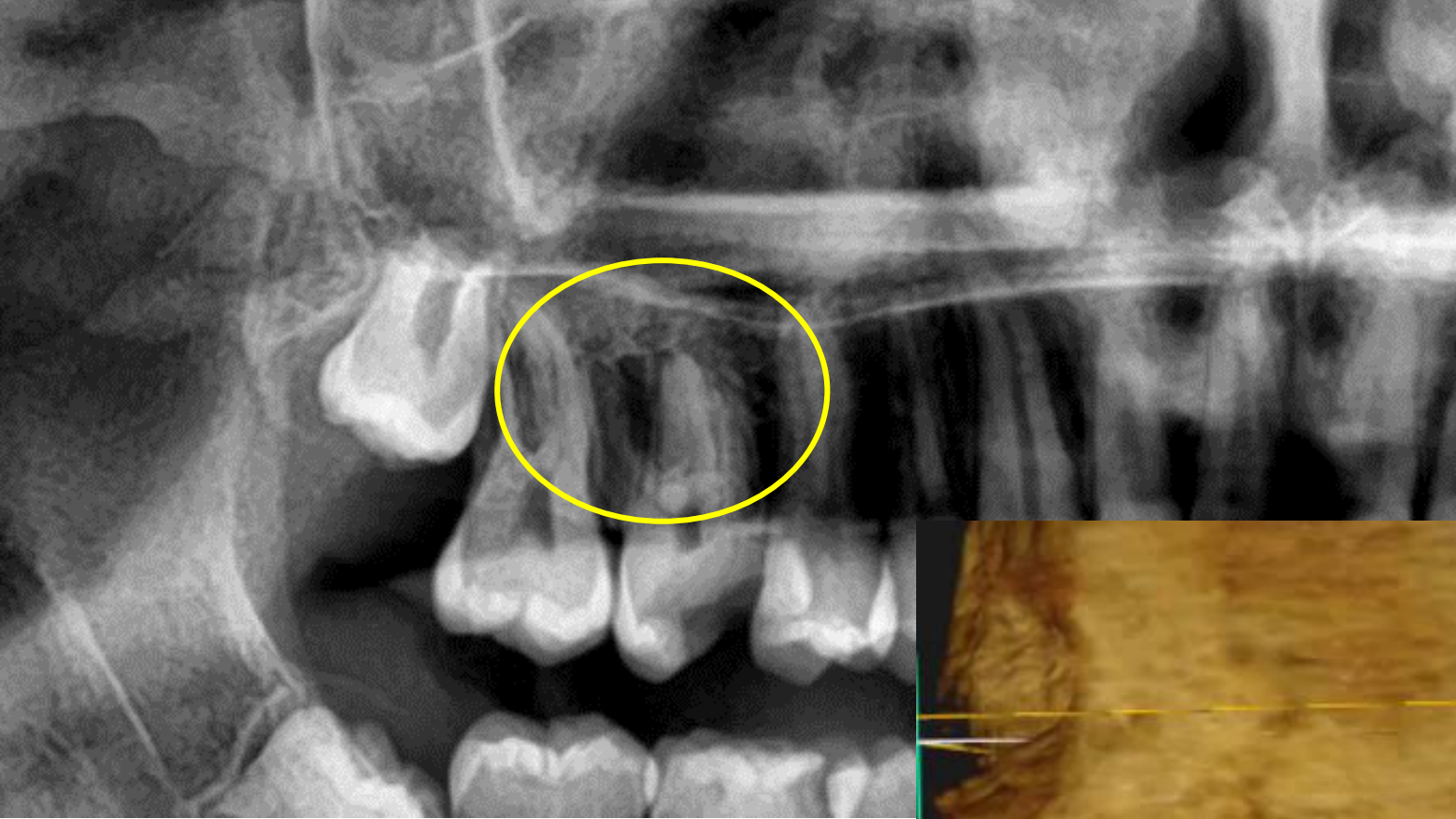
Apical root resorption 0-3%

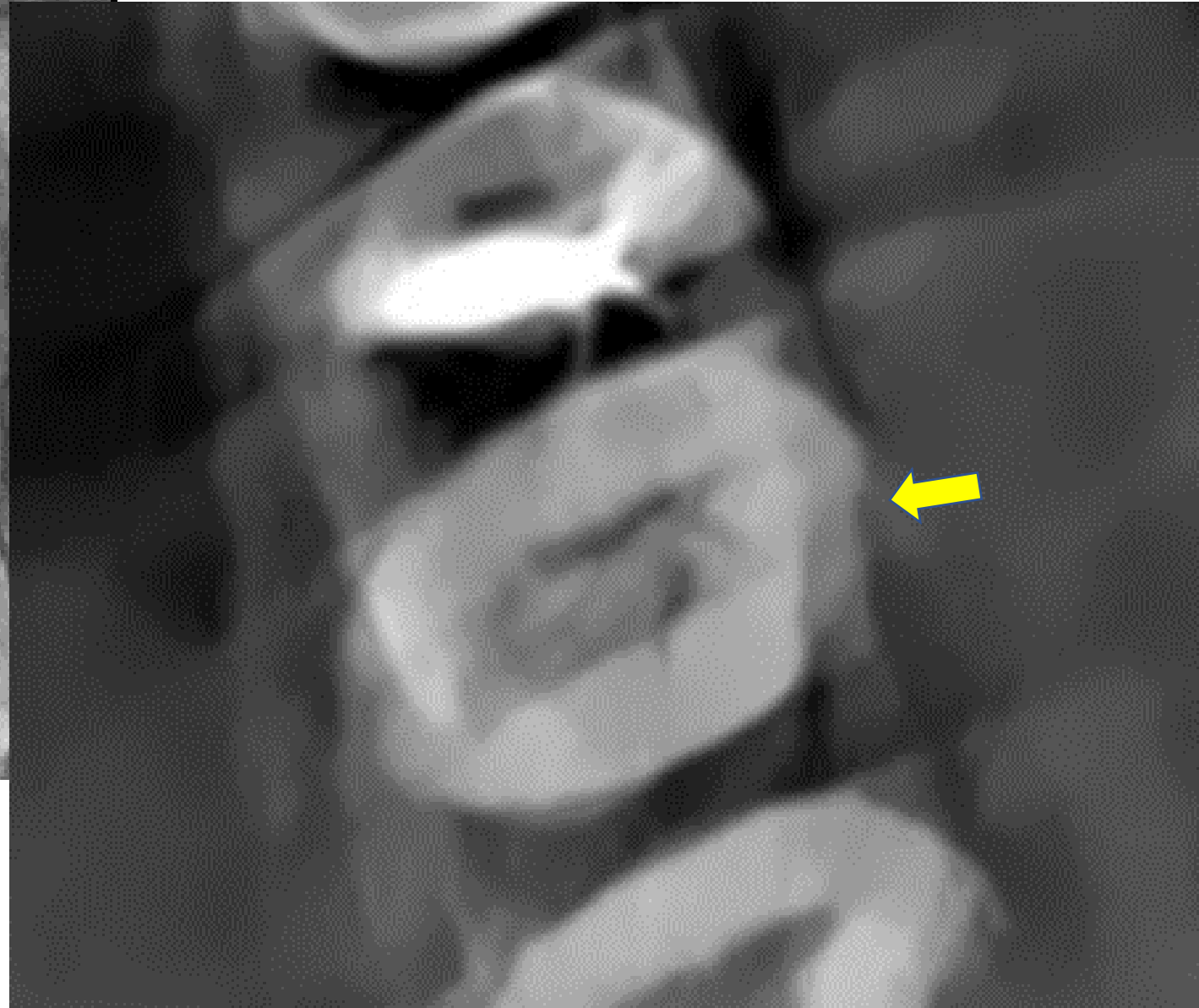
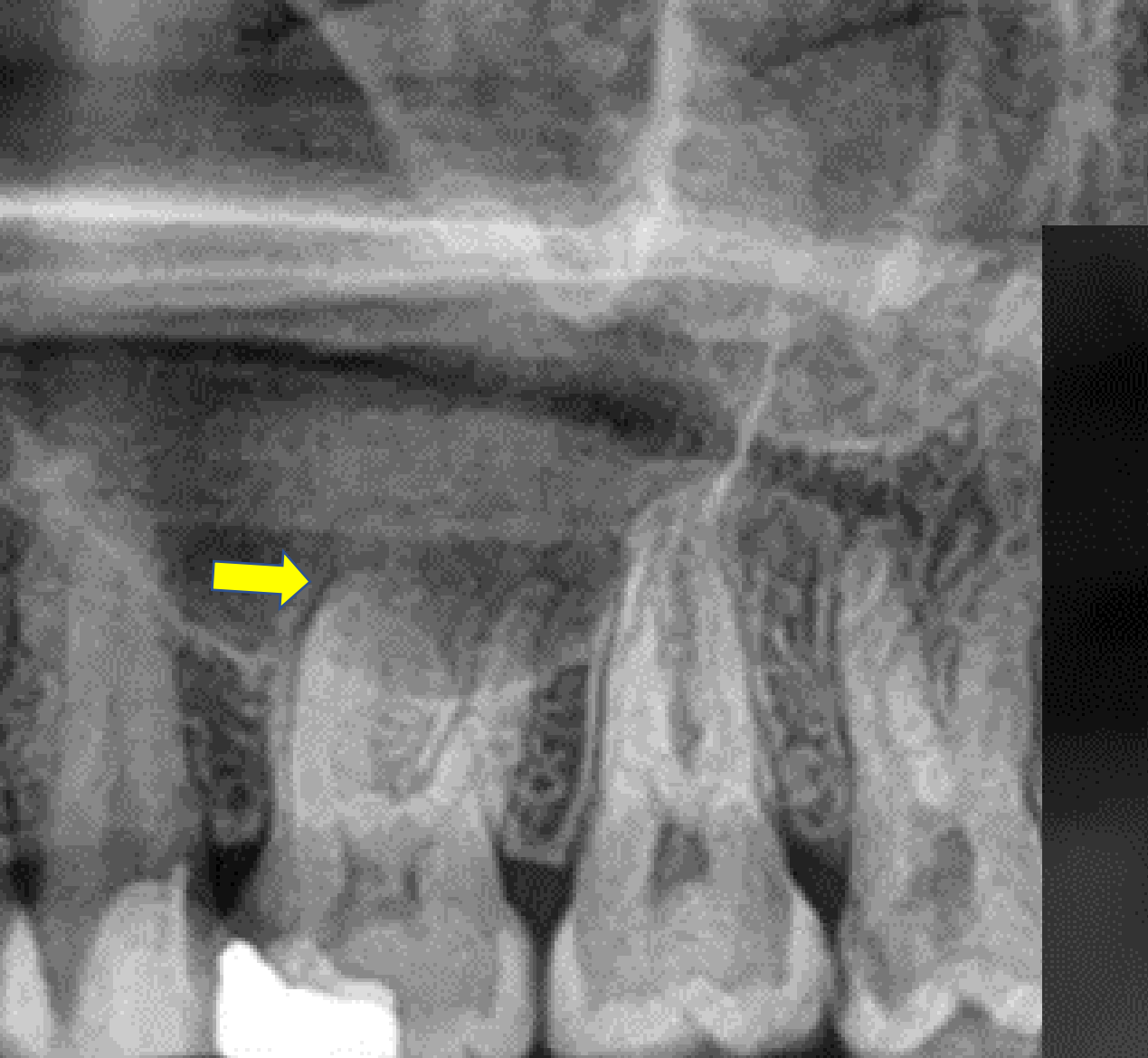
Periapical lesions 4.1-13%

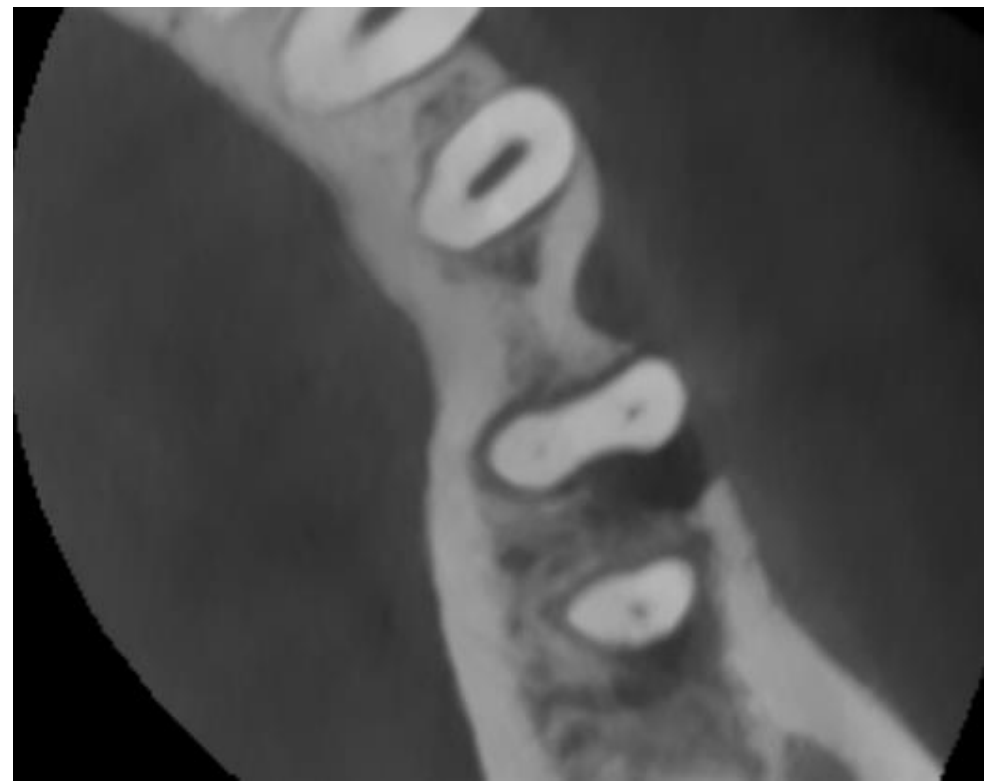
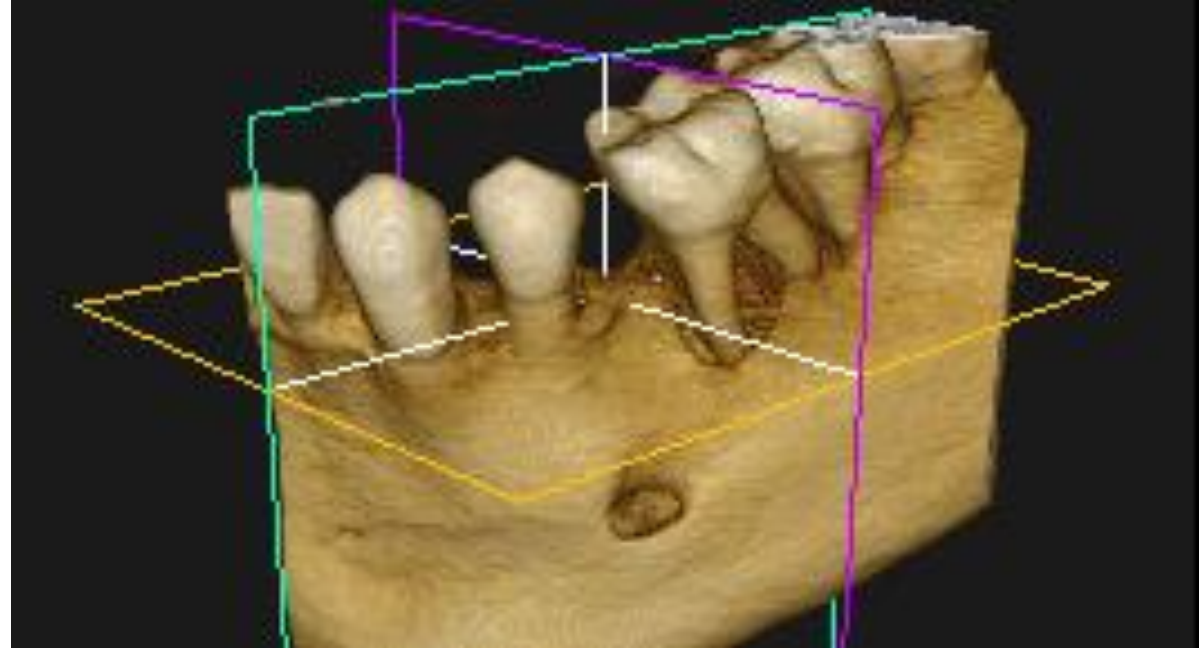
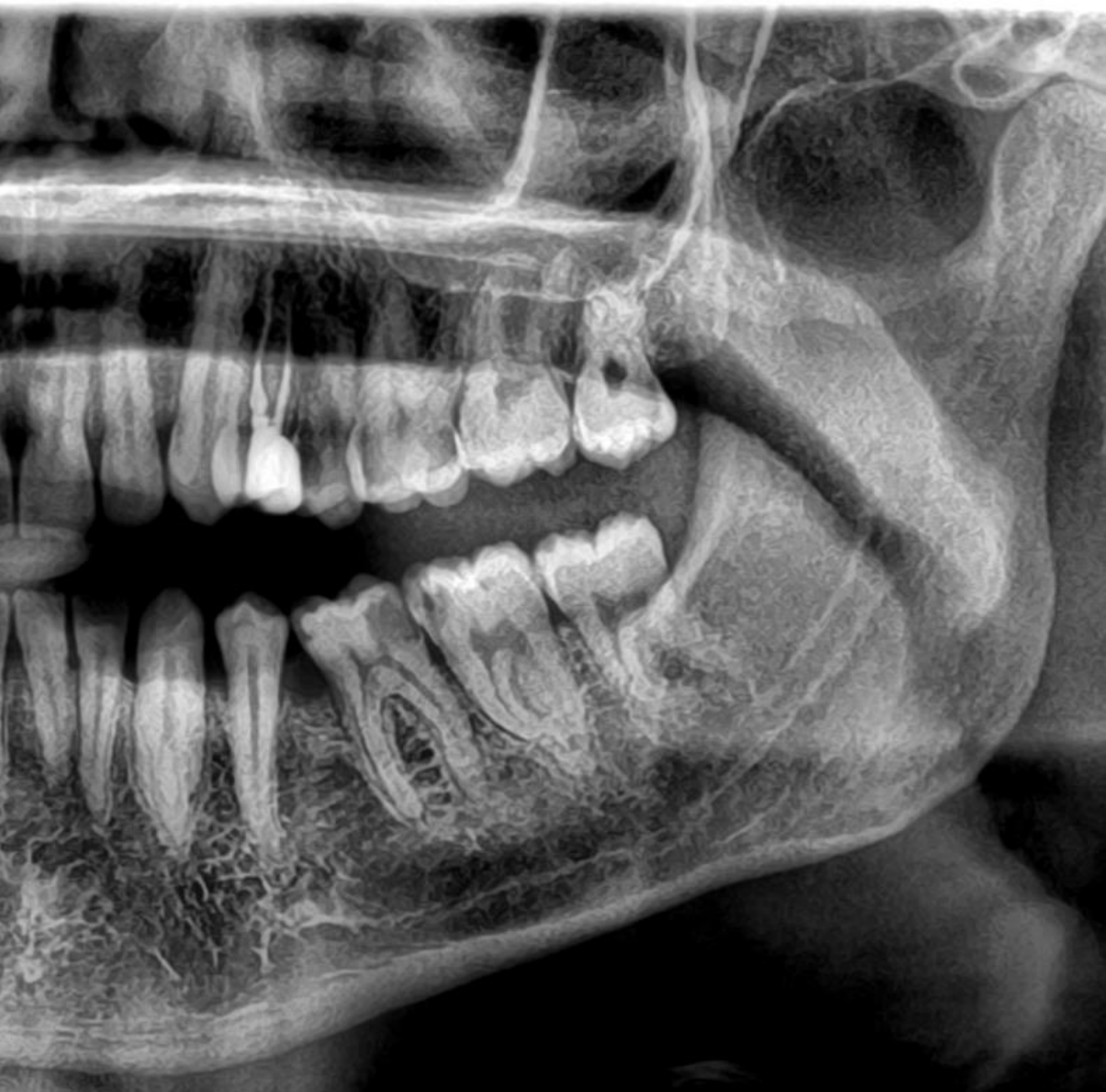



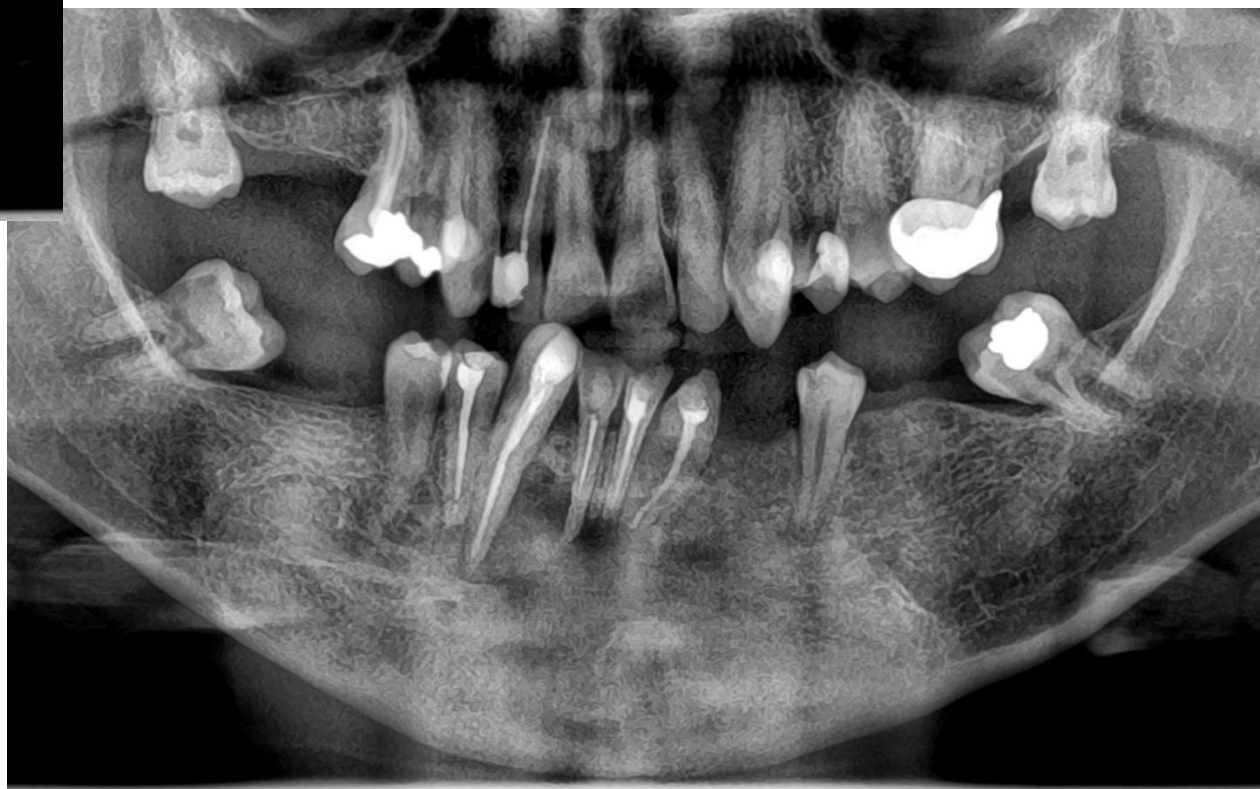
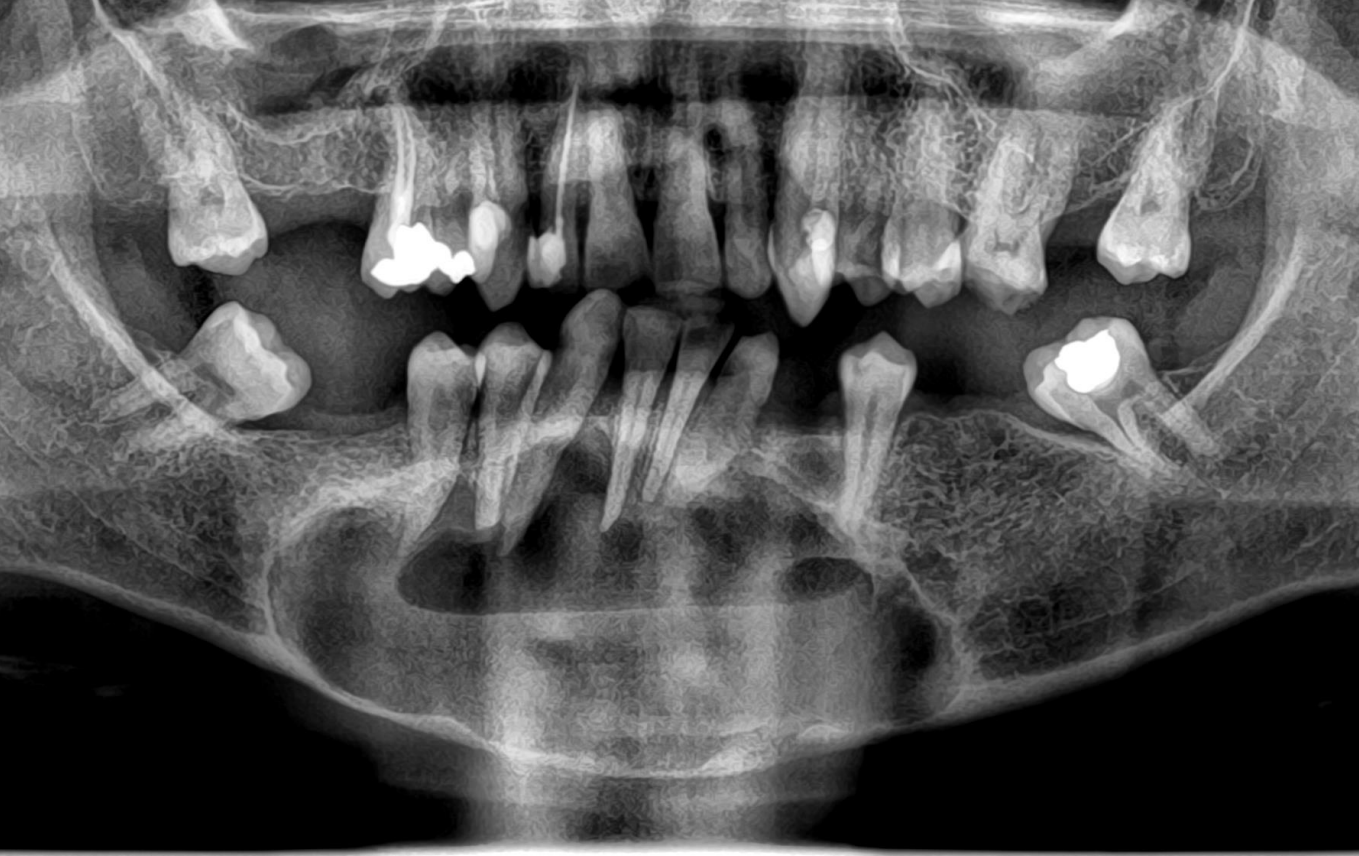




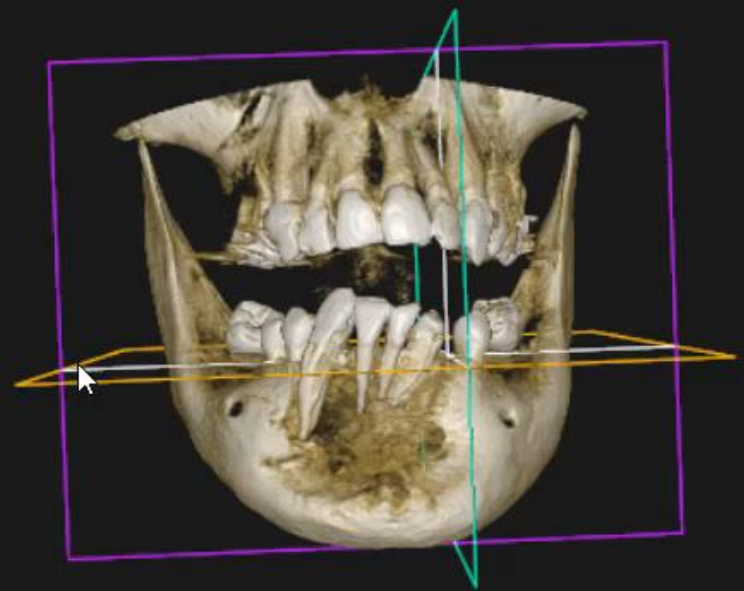




Endodontic Surgery

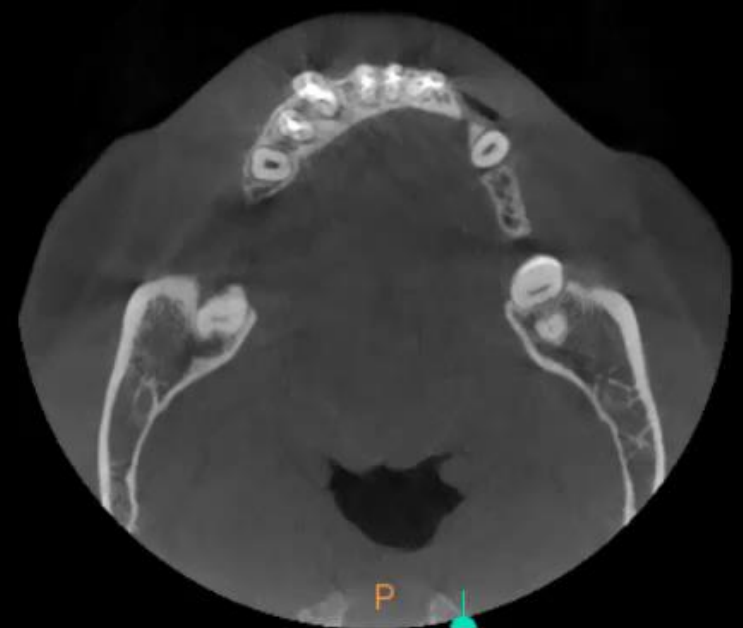

A



37.2 mm
zoom: 0.41

R



FDK

76.0 mm
zoom: 0.41

L A

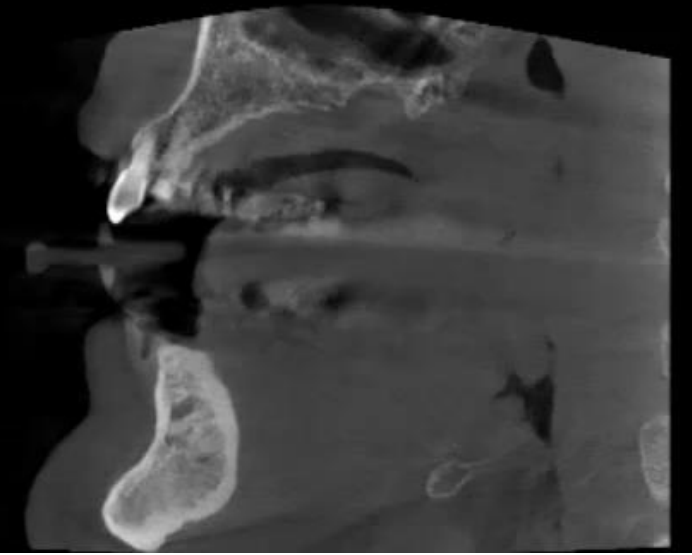
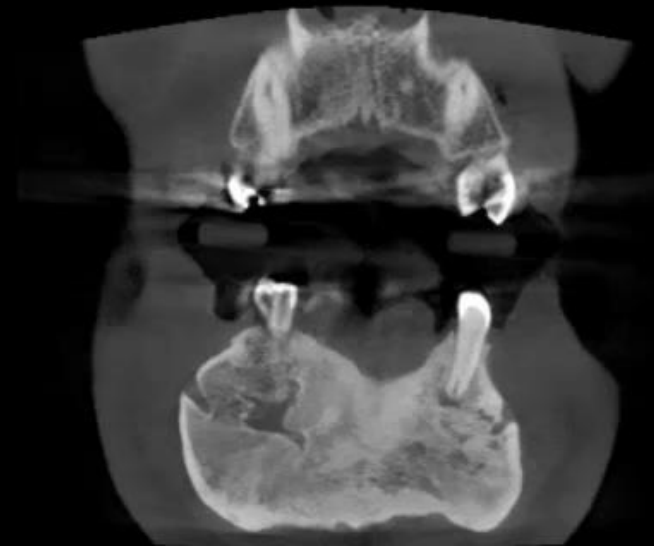


1x1 449 μm

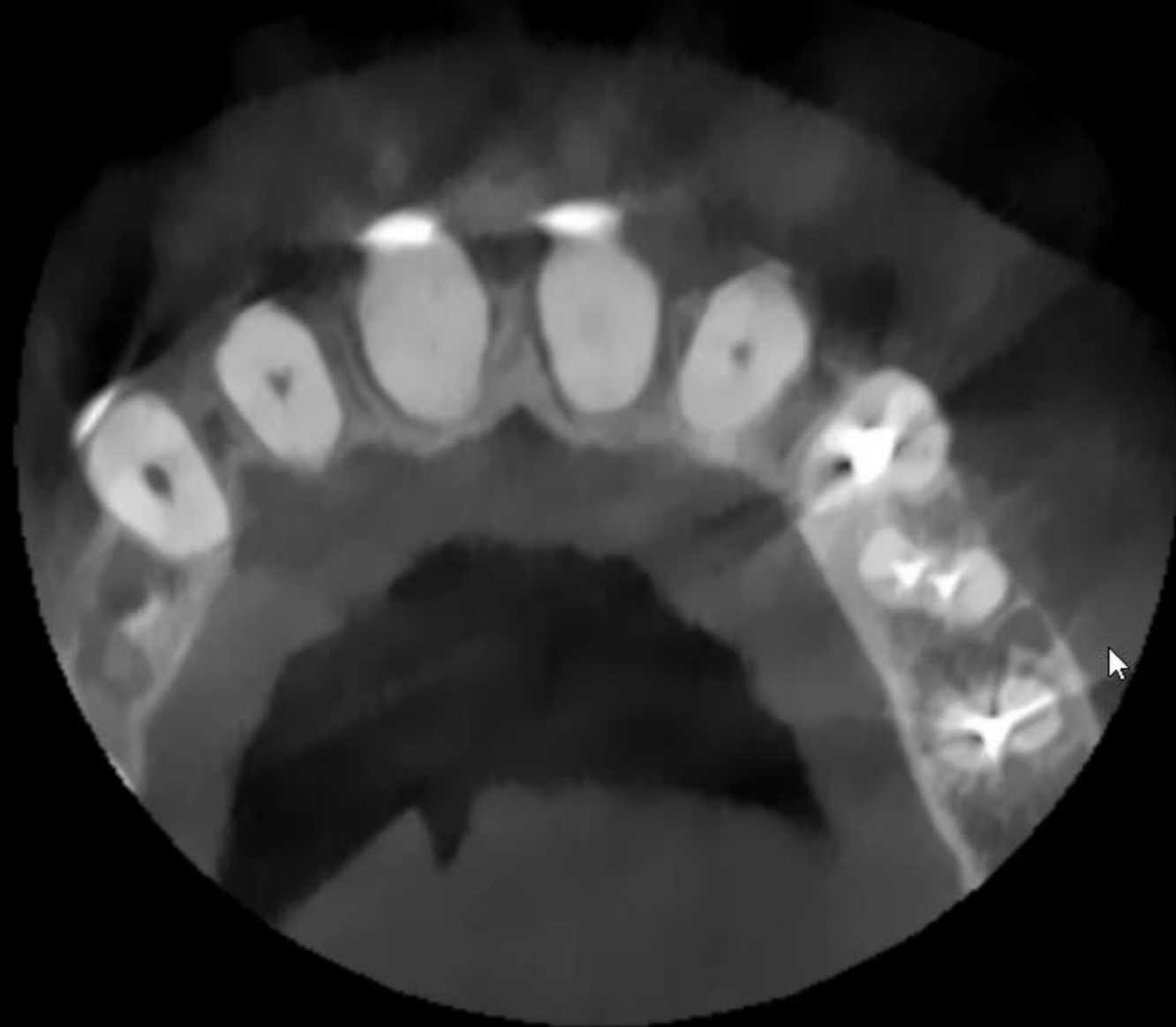
38.5 mm
zoom: 0.41

H

R



**Root
canal
sclerosis**





جمهية حشوات الجذور العراقية Iraqi Endodontic Society

Iraqi Endodontic society IES

Public Group

Joined ▾

Share

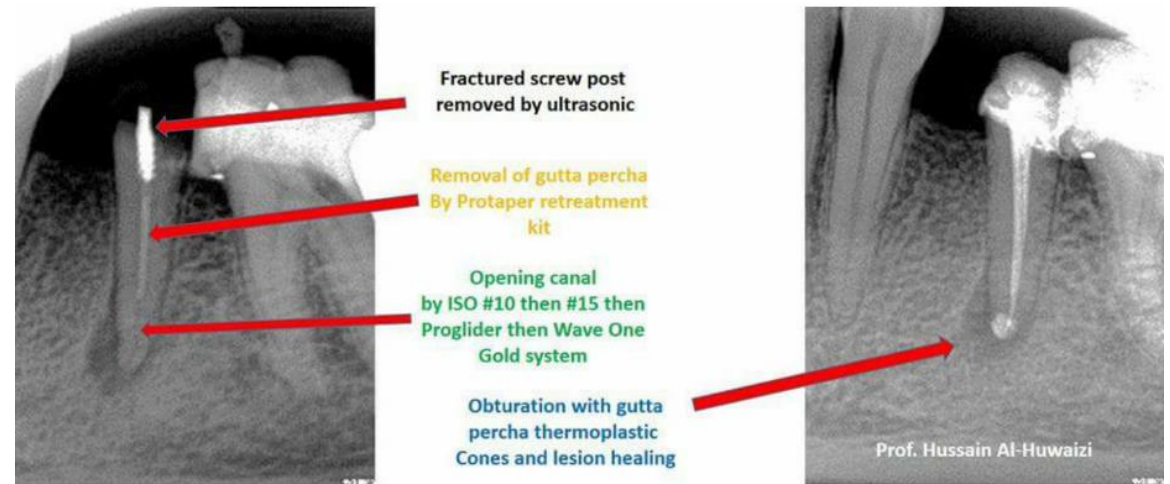
Notifications



Hussain Al-Huwaizi added a new photo. ...

5 MINS • GURGAON, HARYANA • 🌐

More than 9200 members



Management of multiple problems in poorly treated tooth

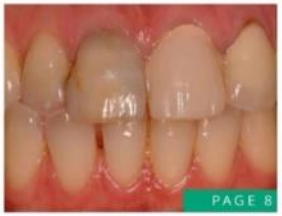Endodontic

CPD Three hours of CPD with this issue

PRACTICE

ENDODONTIC EXCELLENCE FOR DENTAL PRACTITIONERS

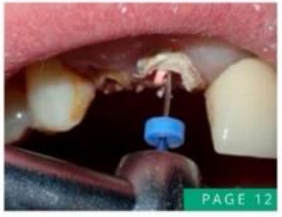ENDODONTIC PRACTICE



PAGE 8

Treating infected roots

Jason Bedford



PAGE 12

The history of metal posts

Jeremy Cooper

Guest editor **Ken Serota**



PAGE 29

Young endodontist
for the future

Yasmin Zeina




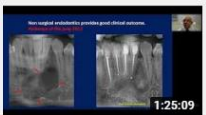


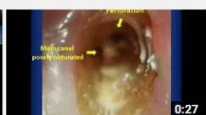










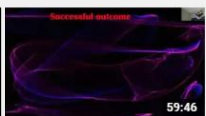





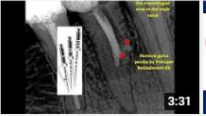


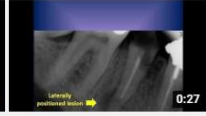
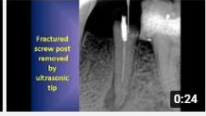
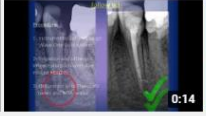




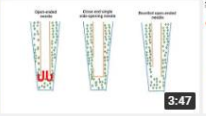


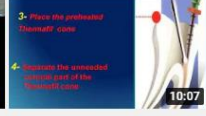


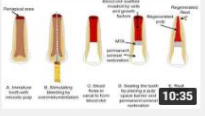


PAGE 38

Achieving endodontic excellence











Sagi Shavit

June 2020 Vol 23 No 2

 Endodontic Microsurgery - Part I. Dr. Raed AlDelayme 871 views • 2 months ago	 Tips and tricks for management of calcified... 1.5K views • 2 months ago	 Endodontic Emergency Treatment 566 views • 2 months ago	 Periapical Lateral lesion healing 419 views • 4 months ago	 Overfilling in Endodontics Part I 716 views • 11 months ago	 Root canal instrumentation strategies by Prof Dr Said... 200 views • 1 week ago	 Treatment of a root canal perforation. 151 views • 2 weeks ago	 Retreatment in Endodontics by Dr. Vresh Chopra 213 views • 2 weeks ago	 Bypassing a separated instrument in a root canal 140 views • 3 weeks ago	 Apical Seal in root canal obturation by Prof. Dr... 218 views • 3 weeks ago
 Overfilling in Endodontics Part II 424 views • 11 months ago	 New challenges in dental treatment- Part II 337 views • 1 year ago	 COVID 19: New challenges in dental treatment- Part I 134 views • 1 year ago	 Antibiotics In Endodontics 473 views • 1 year ago	 Sclerotic canal. How to manage them 543 views • 1 year ago	 Simple steps to remove separated instruments from... 380 views • 1 month ago	 Systematic endodontic treatment planning - Dr... 640 views • 2 months ago	 Endodontic Microsurgery Part III - Dr. Raed AlDelayme 250 views • 2 months ago	 Bypassing separated instrument - Dr. Waleed... 4.7K views • 2 months ago	 Endodontic Microsurgery - Part II by Dr. Raed... 276 views • 2 months ago
 Endodontic regeneration I 1K views • 1 year ago	 Obturation materials Part II 411 views • 1 year ago	 Obturation materials Part I 1K views • 1 year ago	 Management of Root Canal Perforations+sound 447 views • 1 year ago	 Digital radiography in endodontics 1K views • 1 year ago	 Retreatment of poorly obturated teeth 122 views • 1 year ago	 Management of laterally positioned periapical lesion 203 views • 1 year ago	 Management of multiple problems in poorly treated... 106 views • 1 year ago	 Periapical lesion healing after non endodontic... 228 views • 1 year ago	 Management of endodontic emergencies 886 views • 1 year ago
 Pain control in endodontics with sound 712 views • 1 year ago	 Endodontic diagnosis Part II (with sound) 986 views • 1 year ago	 Endodontic diagnosis Part I (with sound) 869 views • 1 year ago	 Root canal irrigation Youtube 1.5K views • 1 year ago	 Root canal obturation materials 900 views • 2 years ago	 Root canal irrigation. New strategies for better cleaning and disinfection 889 views • 1 year ago	 Techniques for obturation of the root canals Part II 1.3K views • 1 year ago	 Techniques for obturation of the root canals Part I 5.6K views • 1 year ago	 Management of root curvatures 252 views • 1 year ago	 Endodontic regeneration II 1.1K views • 1 year ago



YouTube channel- Simplifying Endodontics with Hussain Al-Huwaizi

 Microbiology in Endodontics 706 views • 2 years ago	 Radiography in Endodontics 1.2K views • 2 years ago	 Endodontic Emergency Treatment 2K views • 4 years ago	 Pain Control in Endodontics 1.9K views • 5 years ago	 حفيد الطاء العراقية د حسين فيصل الحوزي 1.3K views • 5 years ago
 Endodontic Diagnosis 2.9K views • 5 years ago	 Endodontic Diagnosis - Bypass of fractured root... 55K views • 6 years ago	 Endodontic Diagnosis - Post endo restoration... 1.4K views • 6 years ago	 Thermofil Obturation 14K views • 7 years ago	 Rotary instrumentation in... 1.2K views • 7 years ago

THANK

YOU