حكمة

دقاتُ قلبِ المـــــرءِ قـــائلةً له

إن الحـــياةَ دقـــائقٌ وثـــواني

فارفع لنفسك بعد موتِك ذكرها

فالذكرُ للإنســـانِ عمرٌ ثاني

Dental Avulsion

م.هبه نافع ياسين

Dental avulsion

- is the complete displacement of a tooth from its socket in alveolar bone. It is also called as “EXARTICULATION” and most often involves maxillary teeth.

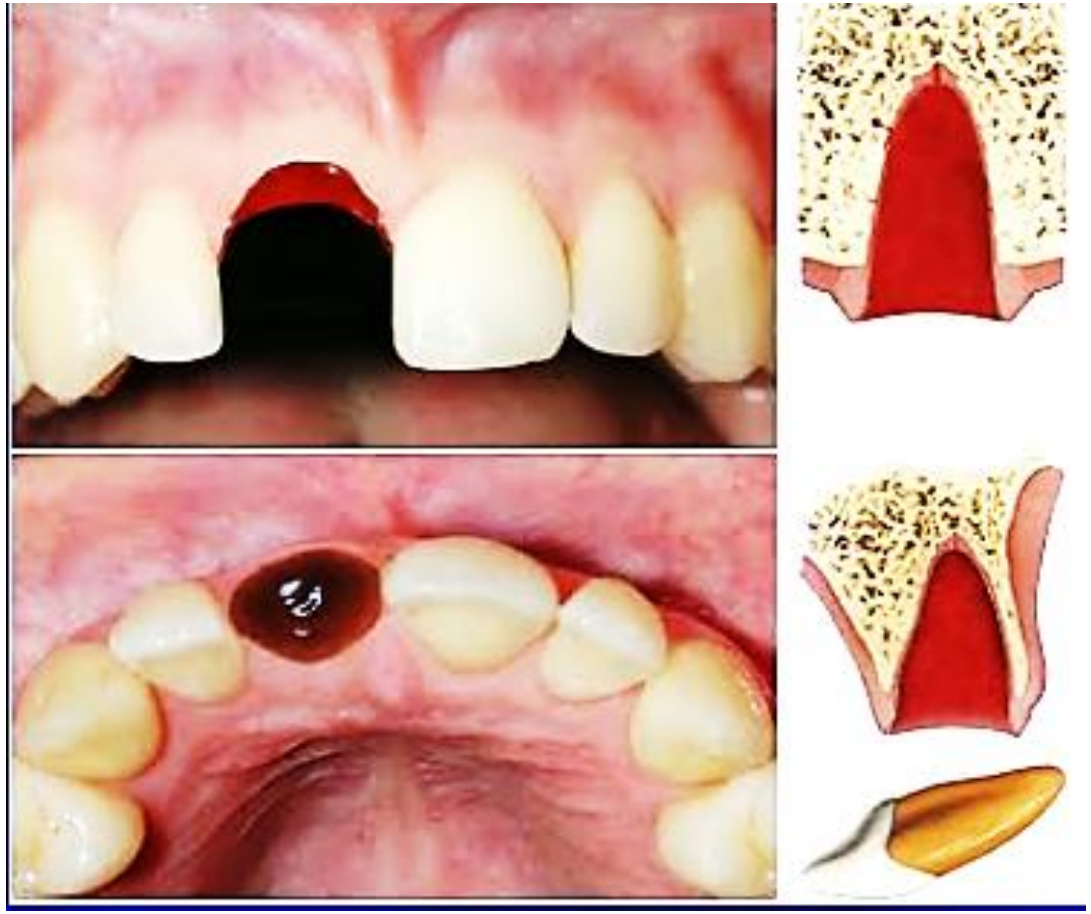

Dental avulsion

- Occurrence: Most commonly a maxillary central incisor
- Sex: Boys 3 times more frequent than Girls
- Age: commonly in children 7 to 9 years of age when permanent incisors are erupting

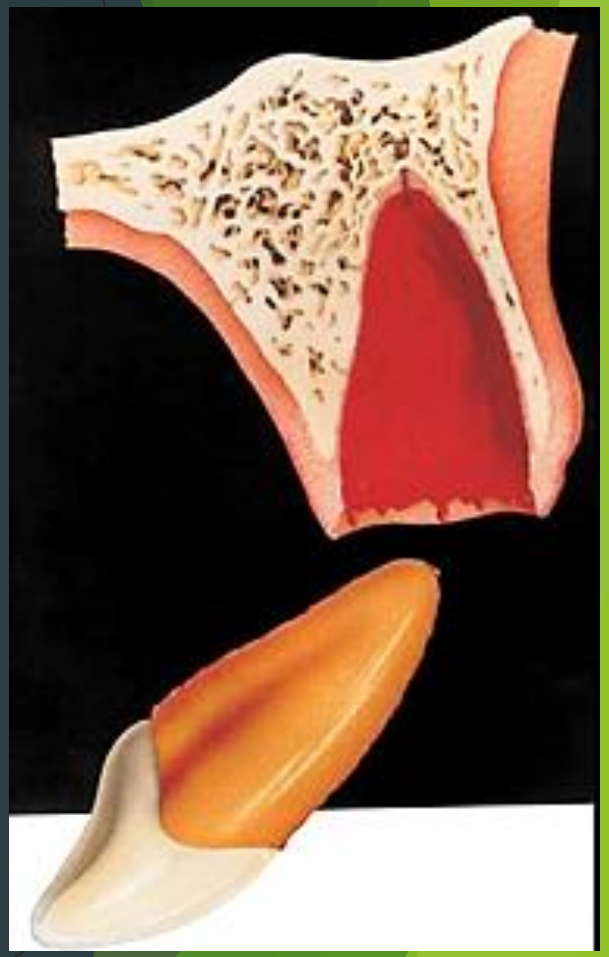

- Andreasen suggests that the loosely structured periodontal ligament surrounding the erupting teeth favors complete avulsion. (McDonald's and Avery, 2011)

CAUSES

- Trauma to the face and mouth from sports or other accidents can cause teeth to fracture, loosen or even knocked completely out of its socket (avulsion)..

CLINICAL FEATURE

- Bleeding socket with missing tooth

RADIOGRAPHIC FEATURES

- Empty socket
- Associated bone fractures
- If the wound is recent then lamina dura is visible, otherwise obliterated

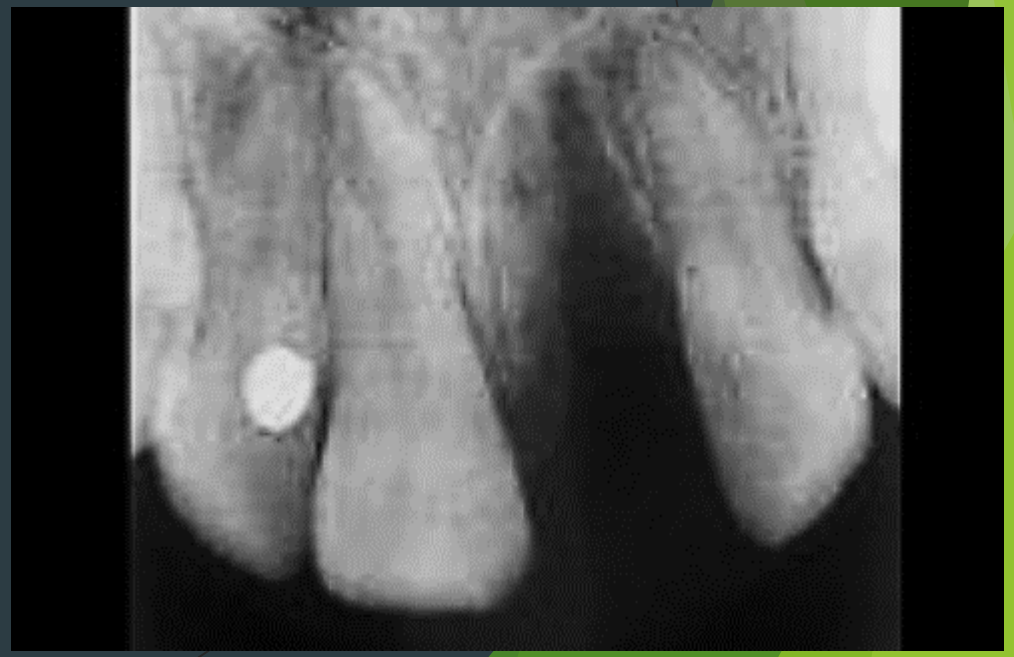

Management can be divided into

A. Management at site of injury
B. Management in the dental office

A. Management at site of injury

- First Aid Advice
  - ✓ Parents,
  - ✓ Caregivers
  - ✓ Teachers



Information can be given over the telephone

- Keep the child calm.
- Locate the tooth and hold by the crown only.
- Replant immediately. If possible. Rinse with cold water (10 seconds only)before replanting if the tooth is contaminated.
- Hold the tooth in place by biting gently on a handkerchief or clean cloth, or use aluminium foil or similar and seek urgent dental treatment.

- If unable to replant the tooth, store it in isotonic media to prevent dehydration and death of the periodontal ligament cells
- Use: STORAGE MEDIA

Types Of Storage Media

1) Saline Solution
2) Tap water
3) Saliva
4) Milk
5) Hank's Balenced salt solution
6) Viaspan
7) Gatarade
8) Propolis
9) Contact lens solution
10) Emdogain
11) Egg white
12) Eagle's medium
13) L-Dopa
14) Coconut water

So which is best

- Neither water nor saliva is as good as milk or saline, if the tooth must be stored for a long period (more than 30 minutes before replantation).

- Because water is hypotonic, its use leads to **rapid cell lysis and increased inflammation on reimplantation**

(McDonald's and Avery, 2011)

1.Tap water

- It is an unaccepted storage media for avulsed tooth.
- It causes increased cell damage due to very low osmolarity.
- Thus, tap water is not suitable as storage media for retaining the viability of PDL cells

2.Saline Solution

Saline solution provides Osmolarity of 280mOsm/Kg despite being compatible to the cells of the PDL.

3.Saliva

- It is used as storage medium for a short period of time.
- Its osmolarity is much lower than the physiologic storage saline (60-70 mOsm/Kg)
- It boots the harming effect of bacterial contamination.

4.Milk

- It is important that it is used in the first 20 minutes after avulsion.
- Favorable results occur due to the presence of amino acids, carbohydrates and vitamins.
- Pasteurisation of milk is responsible for diminishing the number of bacteria

5.Hank's Balenced salt solution (HBSS)

- an avulsed tooth preserving system called – 'SAVE A TOOTH' containing Hank's balanced salt solution(HBSS), a pH preserving fluid and trauma reducing suspension apparatus is available
- This solution is Non-toxic, Biocompatible with PDL cells, pH balanced at 7.2, and osmolarity of 320 mOsm/kg

- هناك سؤال اجابته تكون مختلفه عن كل مرة فما هو هذا السؤال ???
  - كم الساعة الان

- Time is essential! The long-term prognosis of the tooth is severely reduced after 10 min of being dry and out of the mouth.
- Do not waste time searching for an ideal storage medium, replant the tooth!
- Every effort should be directed toward preserving a viable periodontal ligament.

Management at site of injury

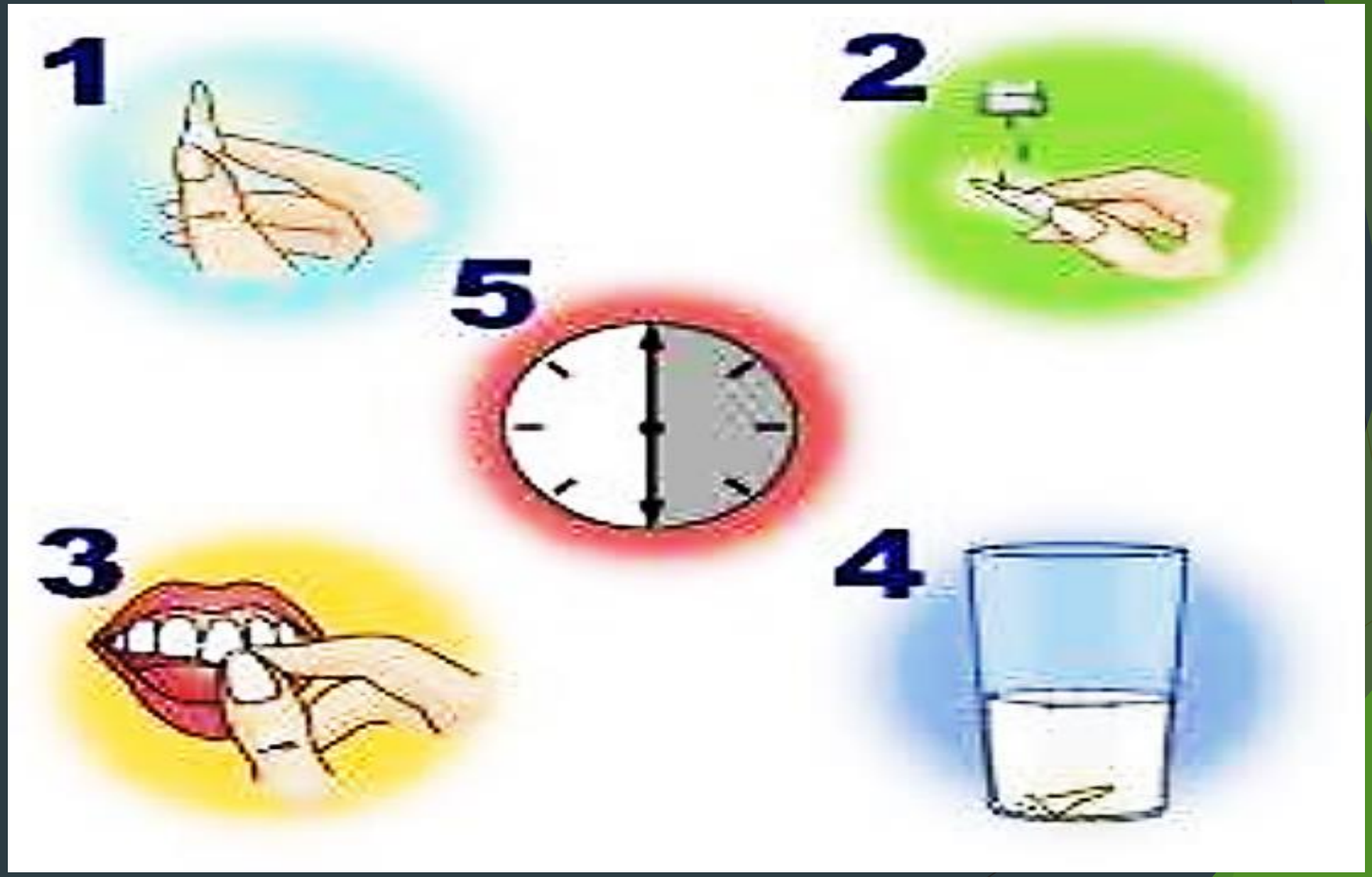

Management in the dental office

It is usually still better to replant the tooth
(Cameron, 2013)

The replanted tooth serves as a space maintainer and often guides adjacent teeth into their proper position in the arch, a function that is important during the transitional dentition period and has psychological value.
(McDonald's and Avery, 2011)

- The single most important factor in the success of reimplantation is the speed with which the tooth is reimplanted. Every effort should be made to re-implant the tooth within first 15-20 minutes.

- Case History should include exact information on :
- 1. Time interval between injury or re-implantation
- 2. Condition under which the tooth has been stored
- The tooth to be stored in storage media like milk, saline, vestibule of mouth, etc.

Replantation

- is the technique in which a tooth, is reinserted into the alveolus after its loss or displacement by accidental means.

Treatment is directed at avoiding or minimizing the resultant inflammation, which occurs as a direct result of the two main consequences of tooth avulsion: attachment damage and pulpal infection.

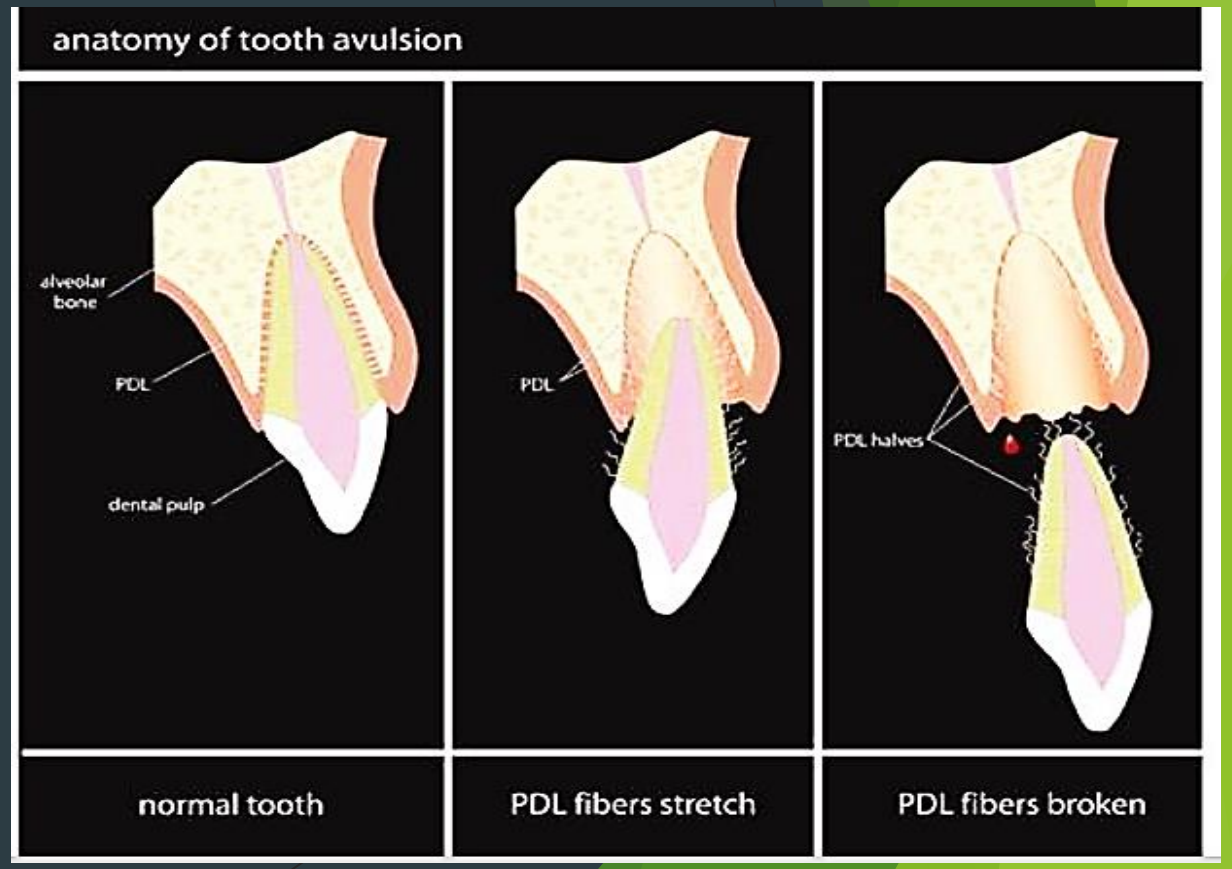

Replant contraindications

- Immunosuppression
- Heart disease (IE risk)
- Extensive periodontal disease
- Carious avulsed tooth
- Alveolus fracture
- Crowding of avulsed tooth
- Primary tooth avulsion

- The faster a tooth can be replanted in its socket after avulsion, the better the prognosis will be for retention without root resorption

Treatment guidelines for avulsed permanent teeth (56–95)

Choice of treatment is related to the maturity of the root (open or closed apex) and the condition of the periodontal ligament cells. The condition of the cells is depending on the storage medium and the time out of the mouth, especially the dry time is critical for survival of the cells. After a dry time of 60 min or more, all periodontal ligament (PDL) cells are non-viable. For this reason, the dry time of the tooth, before it was placed replanted or placed in a storage medium, is very important to assess from the patient's history.

classifying the avulsed tooth into one of the following three groups before starting treatment:

- The PDL cells are most likely viable (i.e., the tooth has been replanted immediately or after a very short time at the place of accident).
- The PDL cells may be viable but compromised. The tooth has been kept in storage medium (e.g., tissue culture medium, HBSS, saline, milk, or saliva and the total dry time has been < 60 min).
- The PDL cells are non-viable. Examples of this is when the trauma history tells us that the total extra-oral dry time has been more than 60 min regardless of if the

Steps of replantation

1- Prepare the Root

- The root surface is contaminated, rinse with Hank's balanced salt solution (HBSS) or saline (use tap water if above are not available)
- Keep the tooth moist at all times
- Do not touch the root surface{hold tooth by the crown}
- Do not scrape or brush the root surface or remove the tip of the root.
- If the root appears clean, replant as it is after rinsing with saline



2- Prepare Socket

A. Anesthesia

B. Do not curette the socket. If a clot is present, use light irrigation with saline.

If the alveolar bone is collapsed and prevents replantation carefully insert a blunt instrument into the socket to reposition the bone to its original position. After replantation manually compress facial and lingual bony plates .

Management in the dental office

3-Replantation of tooth.

- Tooth replanted prior to arrival ,Debride the mouth but do not extract the tooth
- If tooth has been in any physiological storage media, replant immediately..
- If extra oral dry time is less then 15 min, replant immediately if the root apex is closed, subsequently root canal therapy may be required. If the root apex is open replant the tooth and monitor the tooth for pulpal pathosis.

Tooth is dry or extra-oral time is >30 min

- 1 -Remove any necrotic periodontal ligament by soaking the tooth in saline and gently debriding the root surface with saline-soaked gauze.
- 2- The Damage to cementum must be avoided and mechanical instrumentation should be avoided . THE root surface soaked in 2% sodium fluoride and for 20 min. It is essential to the tooth be rehydrated
- 3- Give local anaesthesia and gently debride the tooth socket with saline to remove the blood clot; do not curette the bone or remaining ligament.
- 4 -Replant the tooth gently with finger pressur

4-Splinting of Avulsed Tooth

- Teeth Splints should be flexible to allow normal physiological movement of the tooth; is This helps to reduce the development of ankylosis and replacement resorption

- Rigid stabilization seems to stimulate replacement resorption of the root and detrimental to proper healing of the periodontal ligament

Splint should meet the following criteria

- It should be easy to fabricate directly in the mouth without lengthy laboratory procedures.
- It should be able to be placed passively without causing forces on the teeth.
- It should not touch the gingival tissues, causing gingival irritation.
- It should not interfere with normal occlusion.
- It should be easily cleaned and allow for proper oral hygiene.
- It should allow an approach for endodontic therapy.
- It should be easily removed

(McDonald's and Avery, 2011)

Functional Splinting

- Use acid-etch resin alone or with soft arch wire,or use orthodontic brackets with passive arch wire.

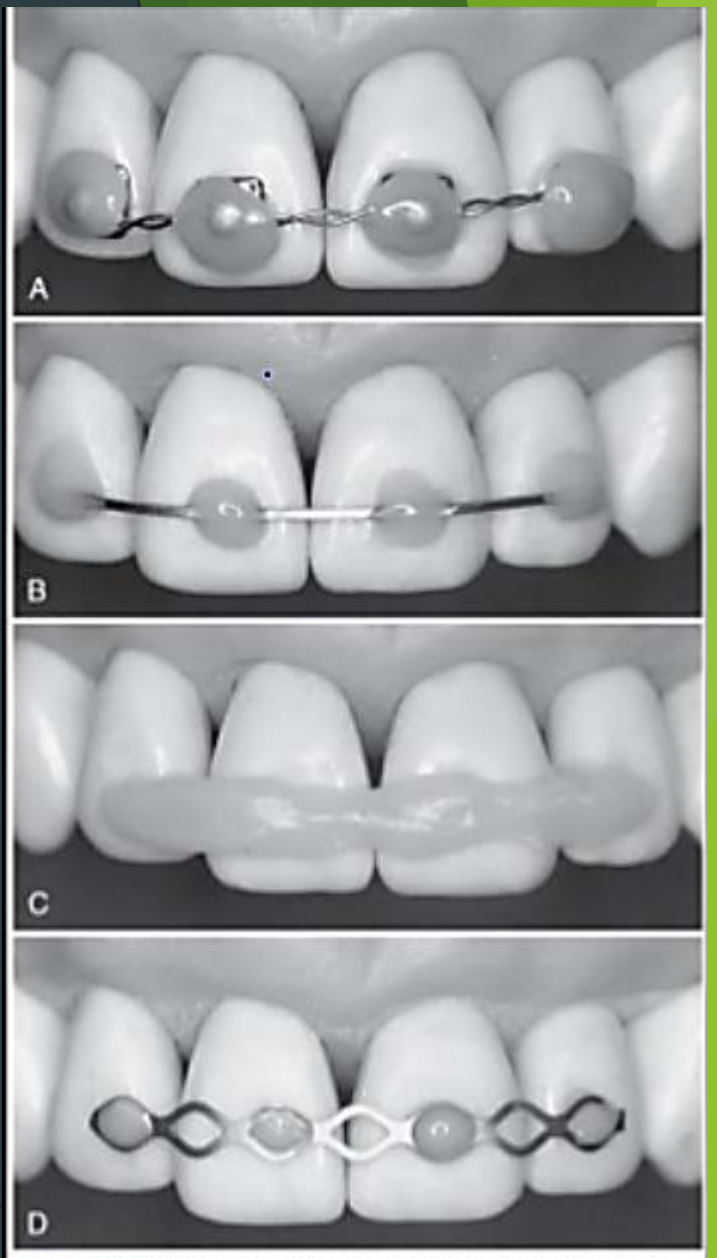

Figure 21-35 Examples of bonded splints. **A,** Button with stainless steel ligature and acrylic caps. **B,** Orthodontic archwire. **C,** Fiber-filled acrylic. **D,** Titanium trauma splint. (Courtesy Dr. Adreas Filippi.)

Timing of splinting

- Splint should remain in place for 7-10 days However if tooth demonstrates excessive mobility splint should be maintained until mobility reduces
- Bone fractures resulting in mobility usually require longer splinting periods (2-8 weeks)

Home care instructions during splinting period include:

1. Do not bite on splinted teeth
2. Soft diet
3. Maintenance of good oral hygiene

Replantation

Endodontic treatment

- Tooth with open apex and less than 15 min extra oral dry time
  - Replant in an attempt to revitalize the pulp
  - Recall patient every 3-4 weeks for evidence of pulpal pathosis.
  - If pathosis is noted, thoroughly clean and fill the canal with calcium hydroxide (apexification procedure initiated).

Tooth with open apex and greater than 15 min extra oral dry time:

- Thoroughly clean and fill the canal with calcium hydroxide. Recall the patient in 6-8 weeks.

Tooth with partially to completely closed apex and less than 15 min extra oral dry time.

- Remove the pulp 10-14 days after replantation
- Medicate the canal with calcium hydroxide
- Obdurate the canal with gutta percha and sealer.

Tooth with partially to completely closed apex and greater than 15 min extra oral dry time.

- Perform root canal therapy either intra orally or extra orally.
- If treated extra orally, avoid chemical or mechanical damage to root surface.
- Avulsed permanent teeth require follow up evaluations for a minimum of 2-3 years to determine the outcome of therapy.

Adjunctive Care:

- Oral/systemic antibiotics (doxycycline)
- Referral to physician for tetanus prophylaxis within 48 hours.
- Chlorhexidine rinses (7-10 days)
- Analgesics (Narcotic)

Patient instructions

- Avoid participation in contact sports.
- Soft food for up to 2 weeks.
- Brush teeth with a soft toothbrush after each meal.
- Use a chlorhexidine (0.1 %) mouth rinse twice a day for 1 week.

- Complications:

- Potential complications of replantation are
  1) Inflammatory resorption
  2) Replacement resorption
  3) Ankylosis

- Andreasen and Hjørting-Hansen reported a follow-up study of 110 replanted teeth. Of those replanted within 30 minutes, 90% showed no discernible evidence of resorption 2 or more years later. However, 95% of the teeth replanted more than 2 hours after the injury showed root resorption

Protocol for management of an avulsed tooth with an open apex[2]

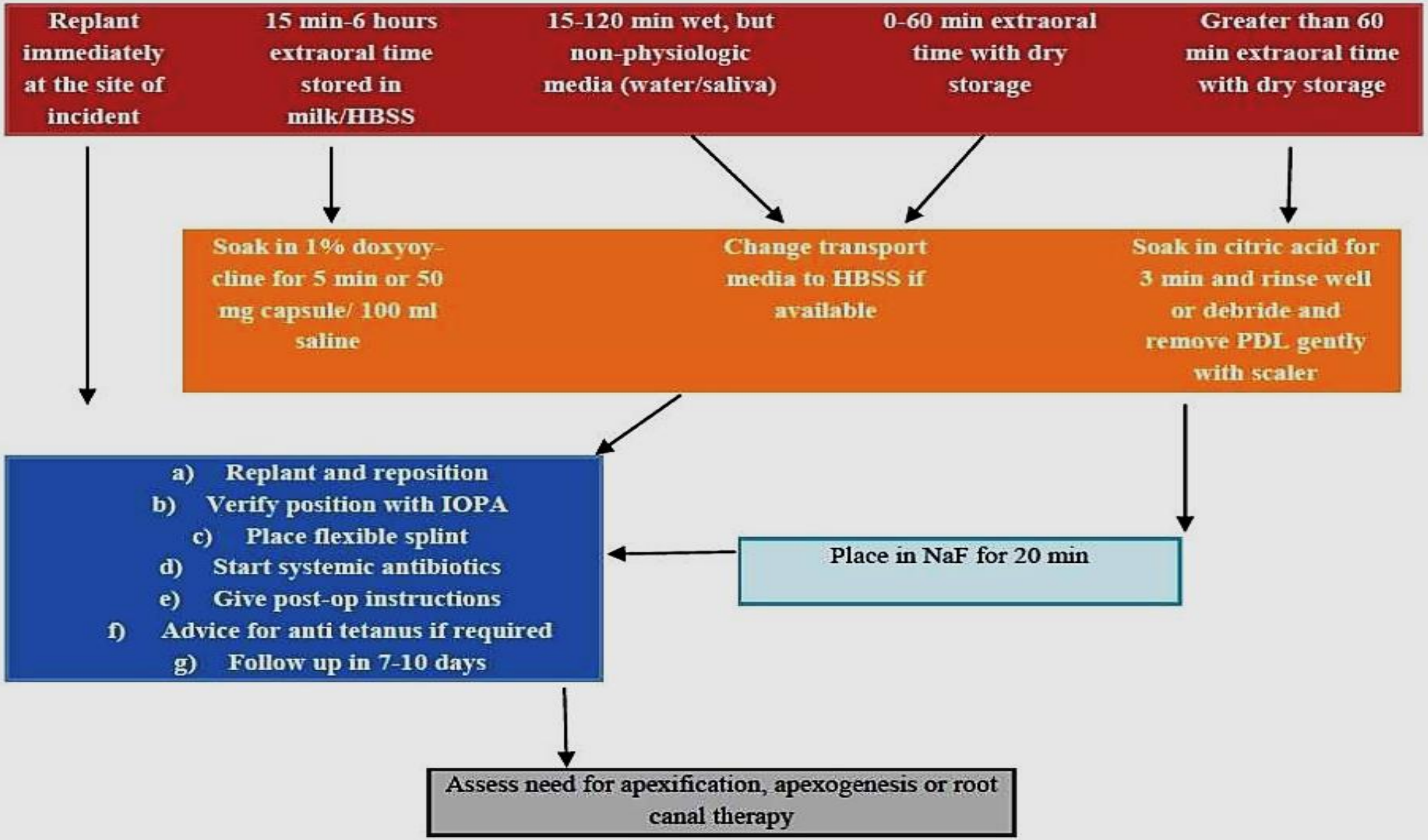

Protocol for management of an avulsed tooth with a closed apex[2]

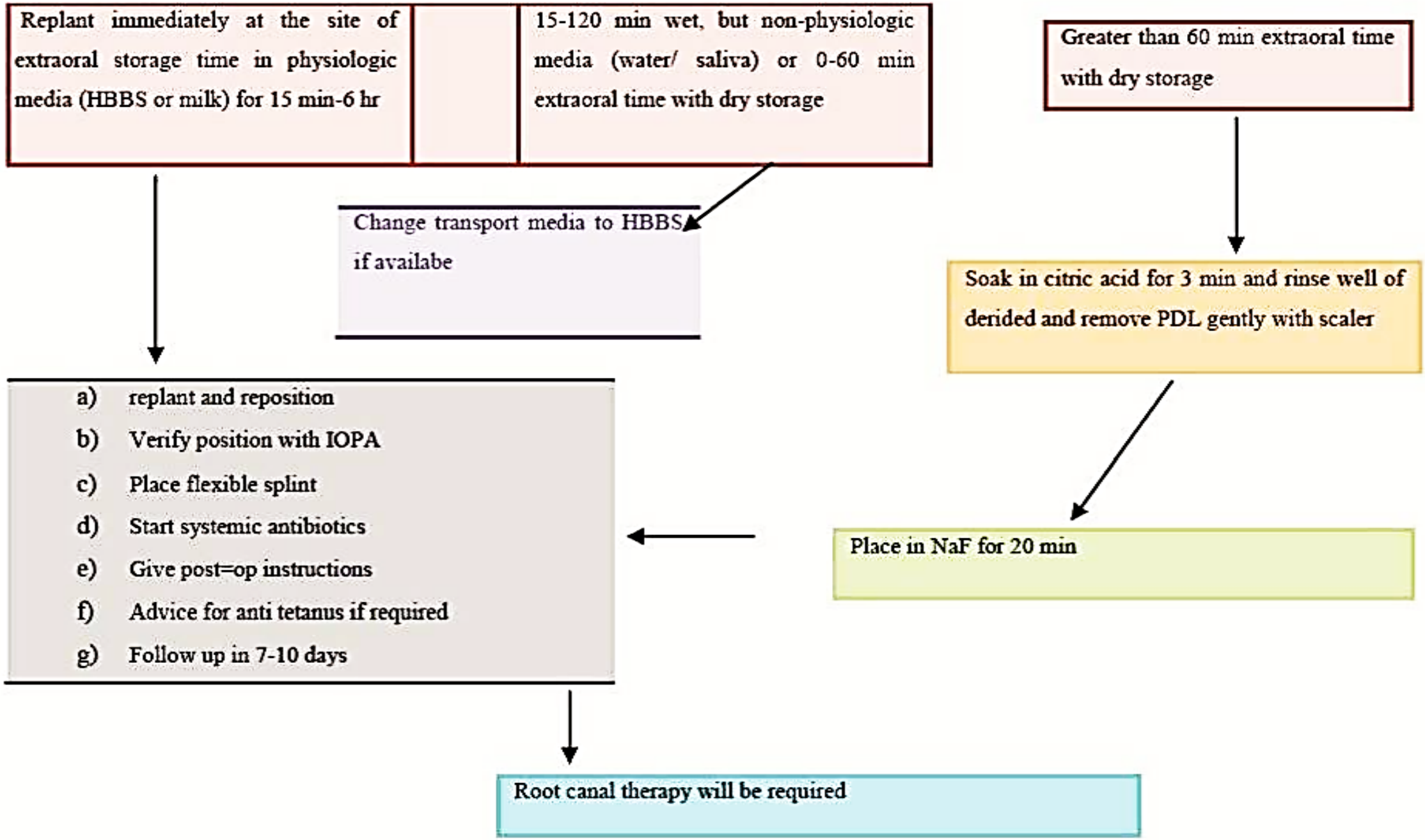

CONCLUSION

- An Avulsed permanent tooth is one of the few real emergency situations in dentistry. Dentist should always be prepared to give appropriate advice to the public about first aid management of avulsed tooth.

REFERENCE

Textbook of Pediatric Dentistry by Nikhil Marwah
Textbook of Pediatric Dentistry by Shobha Tandon

THANK YO