

Clinical Diagnosis of Pet Bird

Asst.Prof. Dr- Amjed. H



Diagnostic pyramid



Taking History
Distant
examination

Physical
examination

Taking History

- ▶ You will ask the owner some questions as:
- ▶ Species of the bird?!
- ▶ Age of the bird?!
- ▶ Sex of the bird?!



Sexing


- ▶ **Female** has bright colors as bright red and purplish blue as in electus with black beak.
- ▶ **Male** has very bright green color with yellow beak.



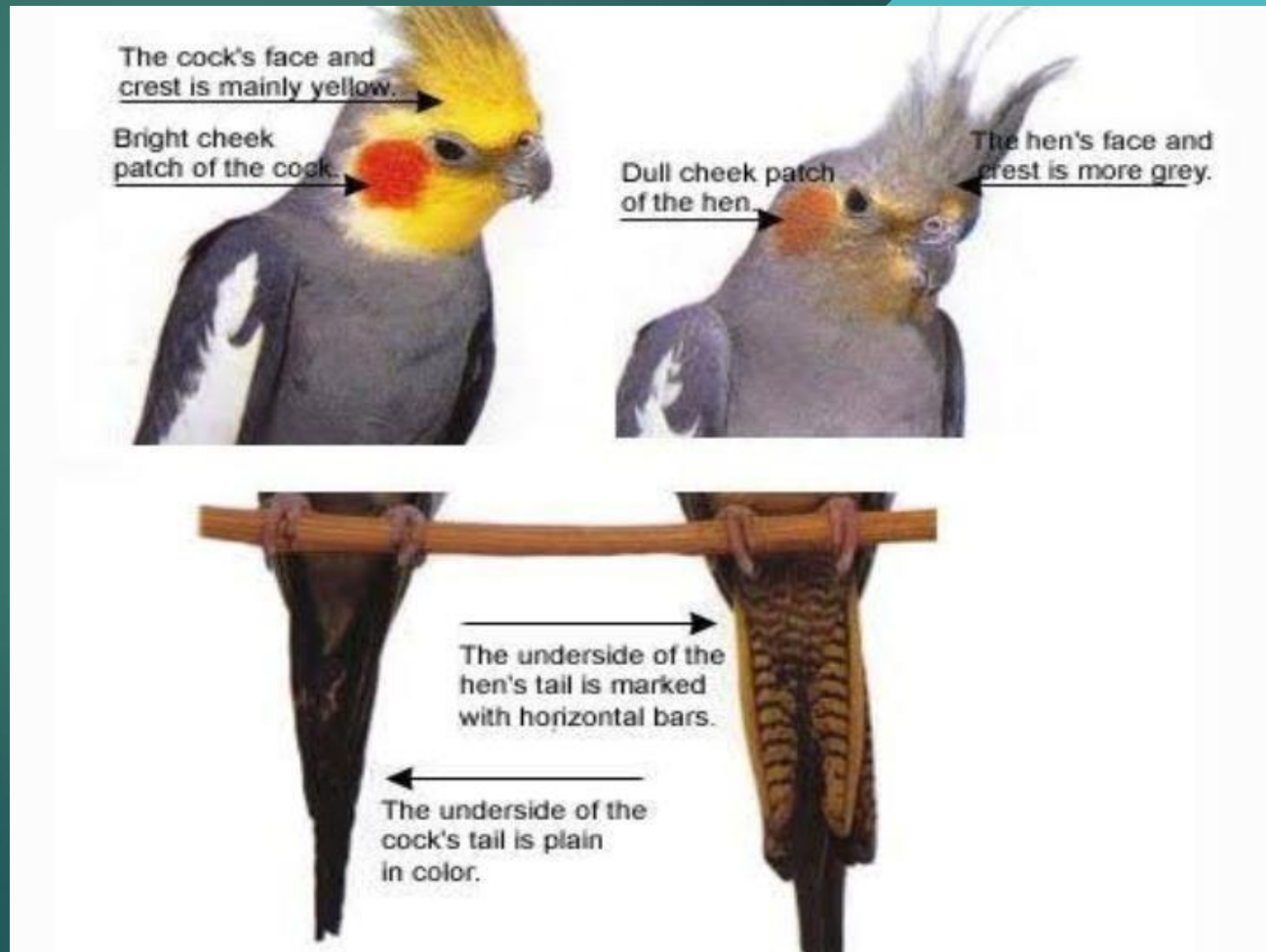Budgies:

We can differentiate from cere .

Cere of male is blue but us brown in female



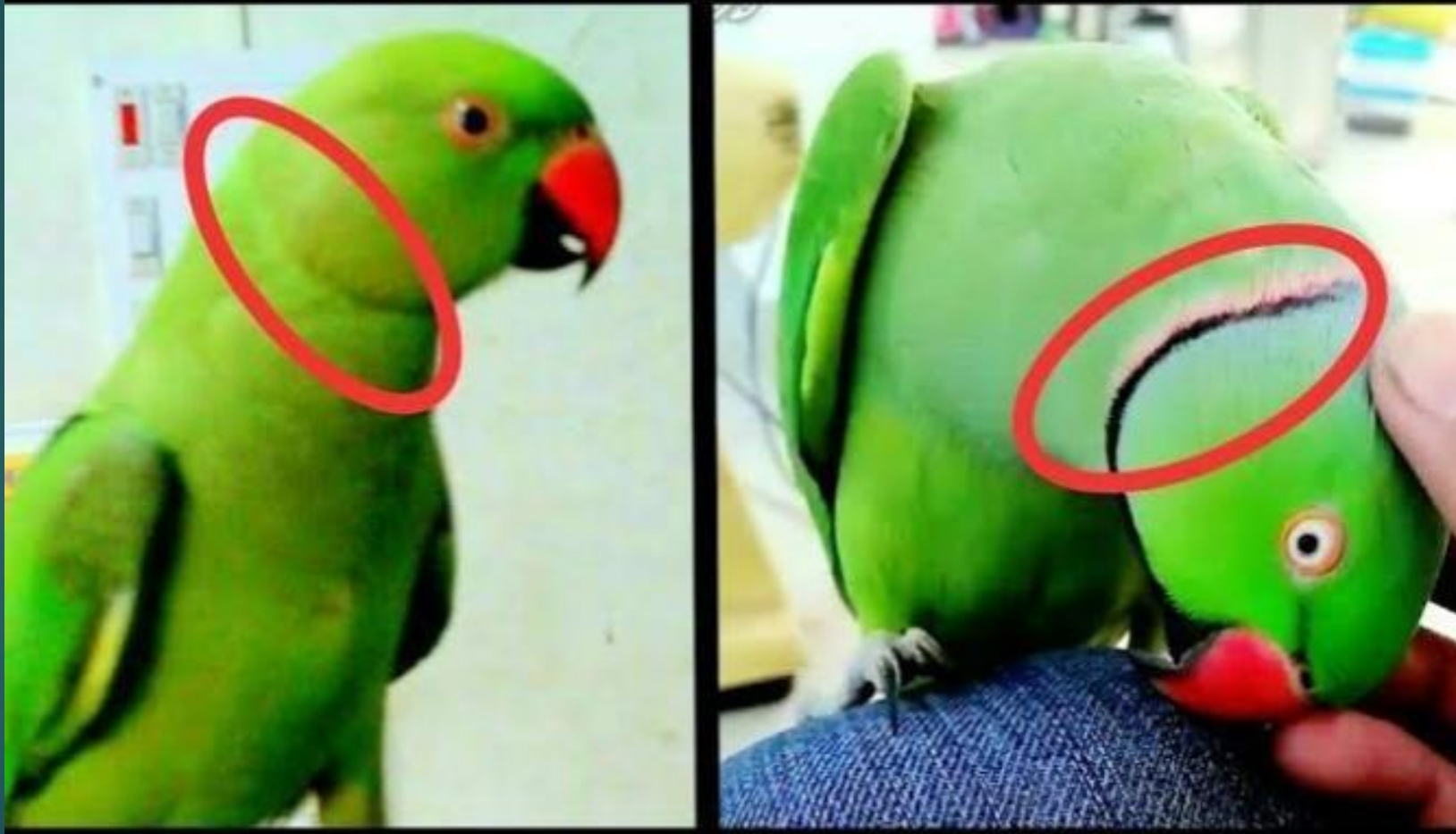
- ▶ **Cockatiel:**
- ▶ Very difficult to differentiate but we can try only after 1st molt.



- ▶ **Canaries:**
- ▶ *Difficult to differentiate but vent in males protrude somewhat in males than females with surrounding skin*



► Ring necked parrots



Pelvic sexing

- ▶ By palpation on ventral abdomen to determine the amount space bet Pelvic bones.
- ▶ In male, there is little space bet Pelvic bone while in female, there is wide space bet. Them.





Aging



- ▶ Does the owner have other Birds and if it is ,Any of this birds have similar clinical signs?!
- ▶ Where the owner keeps the cage, in isolation or in the middle of constant activity?!
- ▶ Is the bird get adequate sleep at night?!
- ▶ Is the bird wild caught or domestic!?



- 
- ▶ *Does the bird has access to direct sunlight?!And if it is protected from predators and diseases*
 - ▶ *Where is the cage located in the house?!*
 - ▶ *How much food is being consumed?!*
 - ▶ *What feeding formula is used?!*
 - ▶ *What is the temperature of the food ,quantity, frequency and method?!*

- 
- ▶ *Is the food prepared freshly diet?!*
 - ▶ *Are dishes cleaned every day?!*
 - ▶ *Are vits and minerals supplement being administrators?!*
 - ▶ *Does the bird get any treats?!*

Ask about previous medical history?!

- ▶ *Has the bird been ill before?!*
- ▶ *If so, what were clinical signs, tests performed, results of those tests?!*
- ▶ *What was diagnosis and therapy?*
- ▶ *What was the response of the bird to therapy?!*

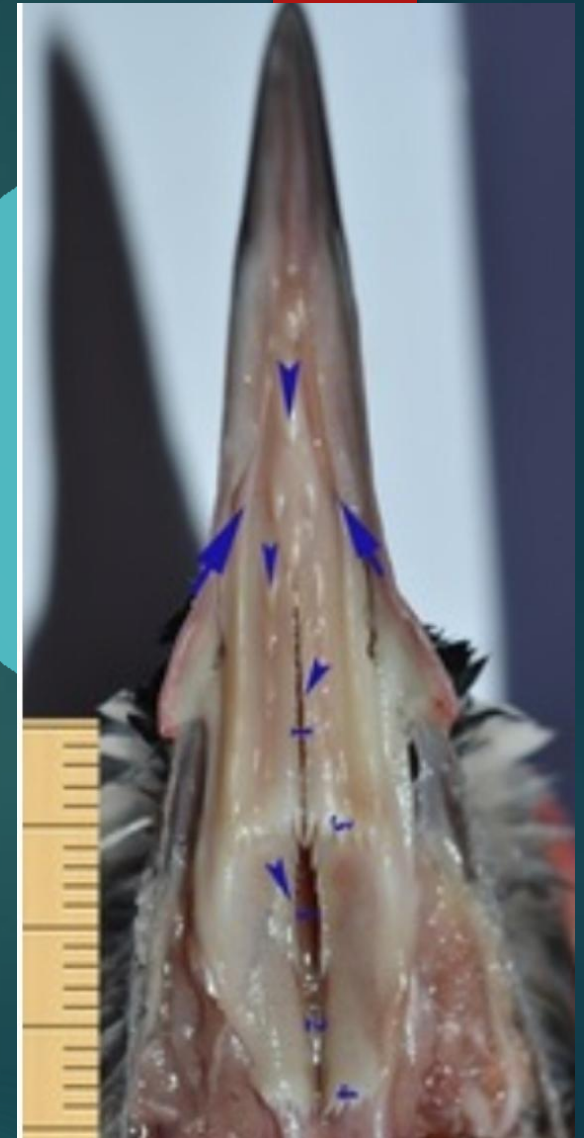
Distant examination

- ▶ *Cage?!*
- ▶ *Odour?!*

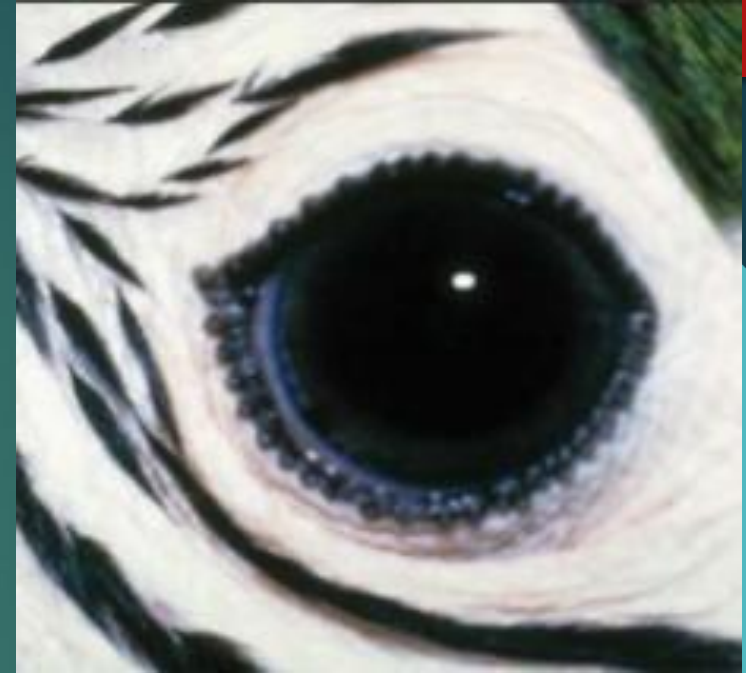
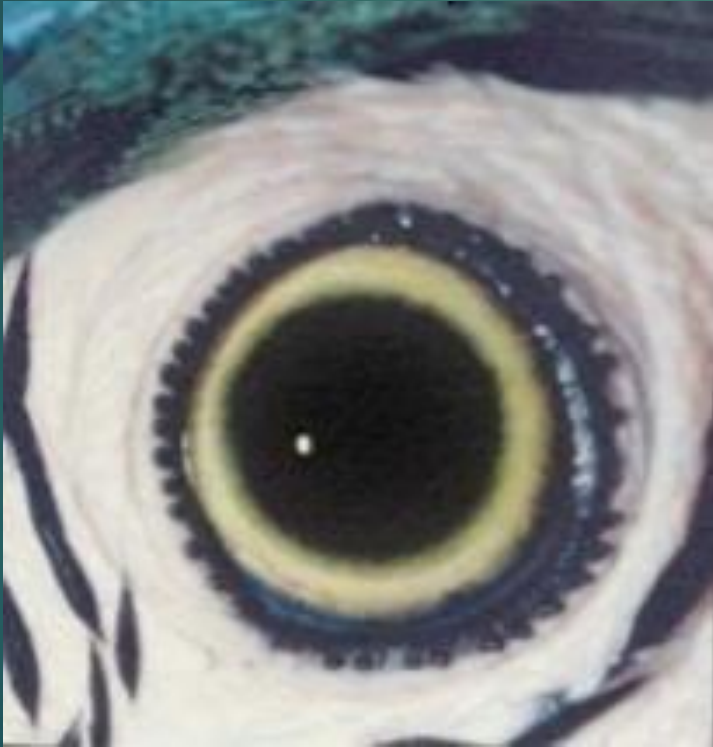
Physical examination

- ▶ **Body condition?!**
- ▶ **Bleeding?!**
- ▶ **Plumage?!**(Color of feather, tidiness of feather, Feather damage, wing clipping, Absence or presence of stress or bars line?!, parasites!)
- ▶ **Head?!**
- ▶ **Body?!**
- ▶ **Crop?!**
- ▶ **Legs and feet?!**
- ▶ **Eye?!**
- ▶ **Ear?!**



Dark and light Iris



***If there is a problem in Respiratory
or cardiovascular system?!***

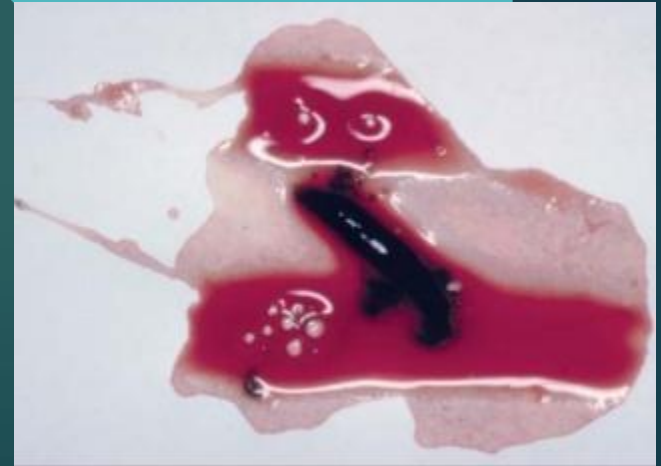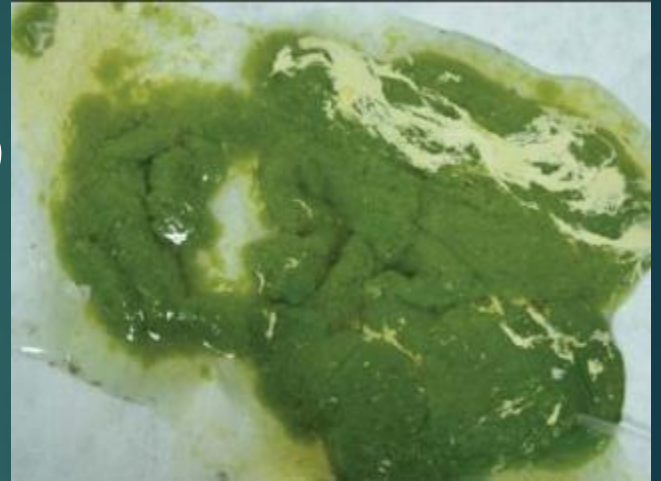


If there is a problem in nervous system?!



Fecal examination?!

- ▶ Malodorous dropping (Bacterial or fungal overgrowth)
- ▶ Aerated dropping or popcorn stool (Giardiasis).
- ▶ Green urates (liver disease).
- ▶ Yellow urates (anorexia or bilirubin excess).
- ▶ Pink or red urates (Renal disease).
- ▶ Pink to brown in Amazon, electus, galahs (poisoning).
- ▶ Orange urates (Injection of excess vitB in diet or artificial colors in diet).
- ▶ Thick, pasty urates (dehydration).



Weighing?!!



Stethoscope?!


- ▶ ***Normal Heart Rate =282 beats per minute***
- ▶ ***Normal Respiration Rate:***
- ▶ ***In small breed (lower than 300 gm)***
- ▶ ***R.R=30-60 per minute***
- ▶ ***In large breed (400 to 1000 gm)***
- ▶ ***R.R=15-30 beat per minute.***



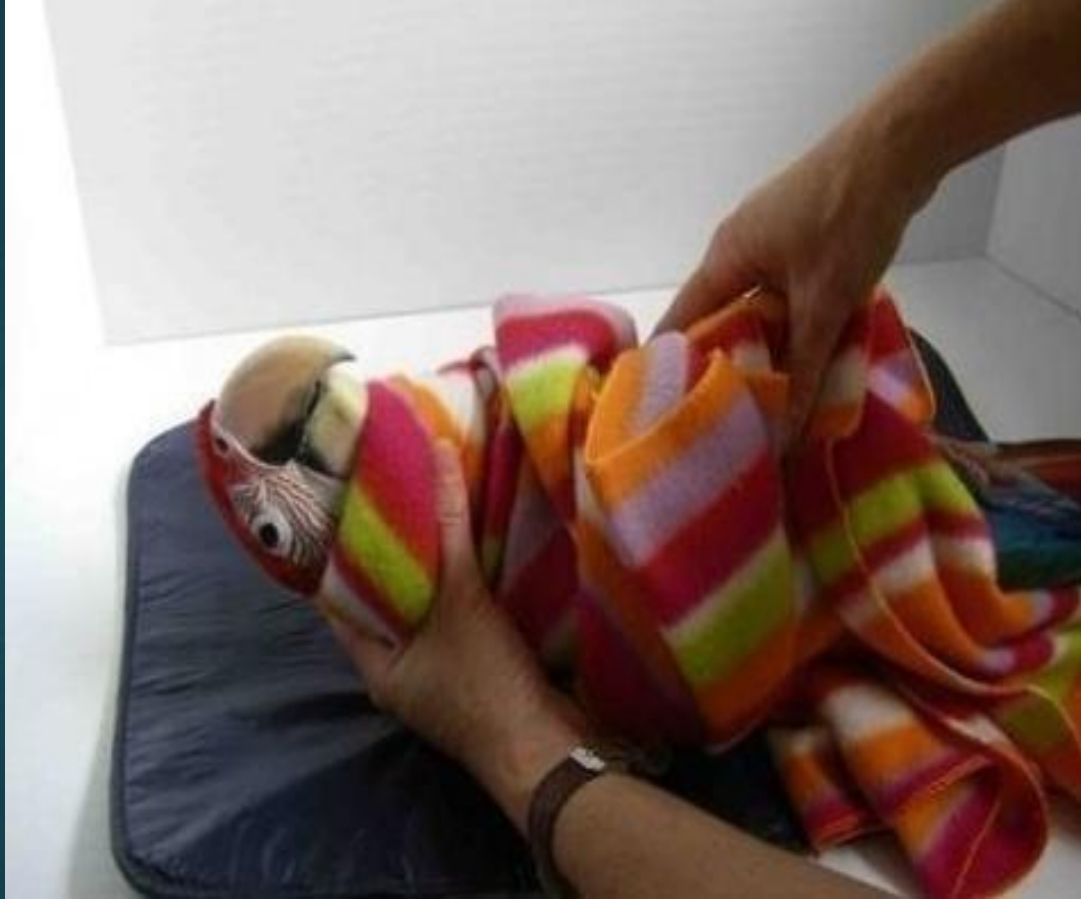Temperature measure

- ▶ *Normal temp=65-80 degree Fahrenheit.*



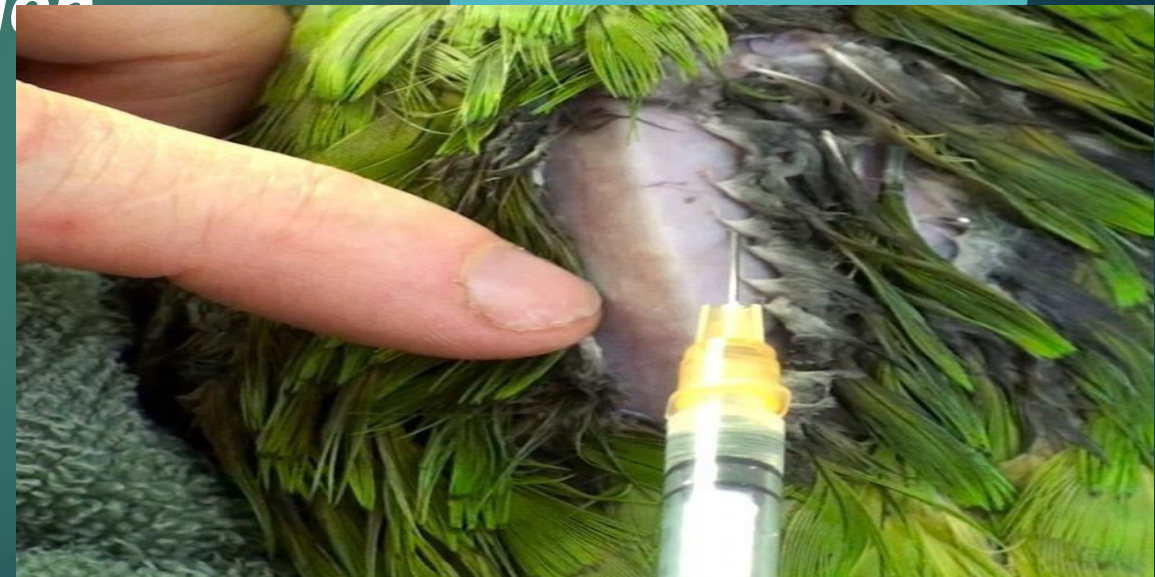
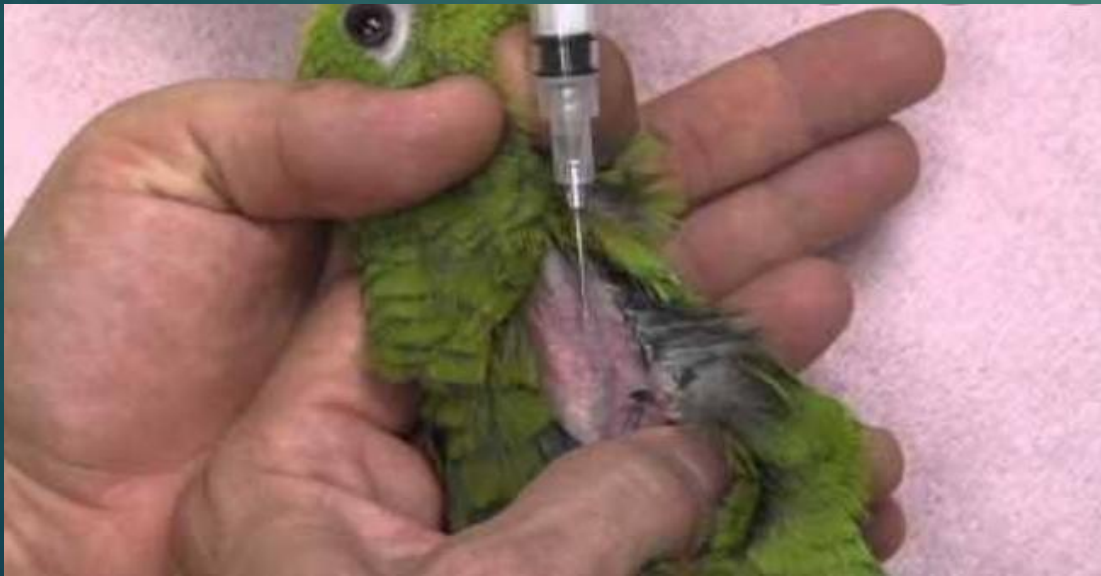
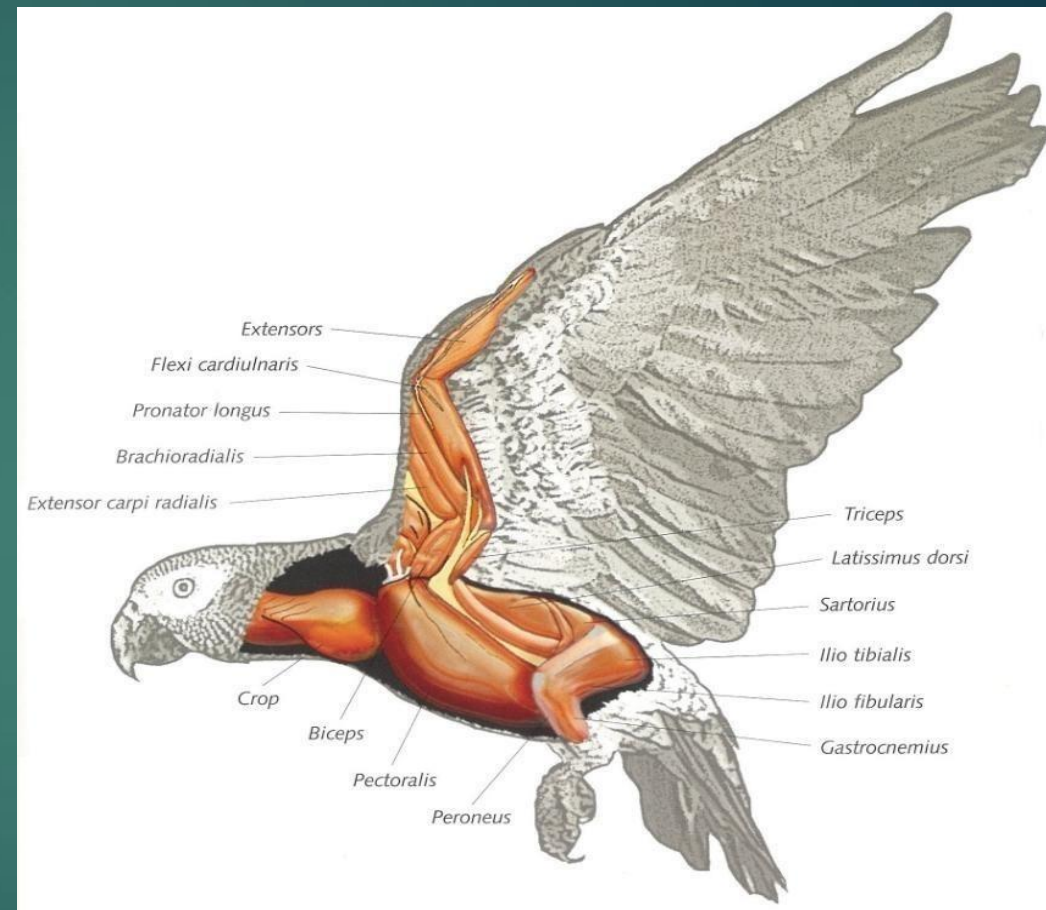
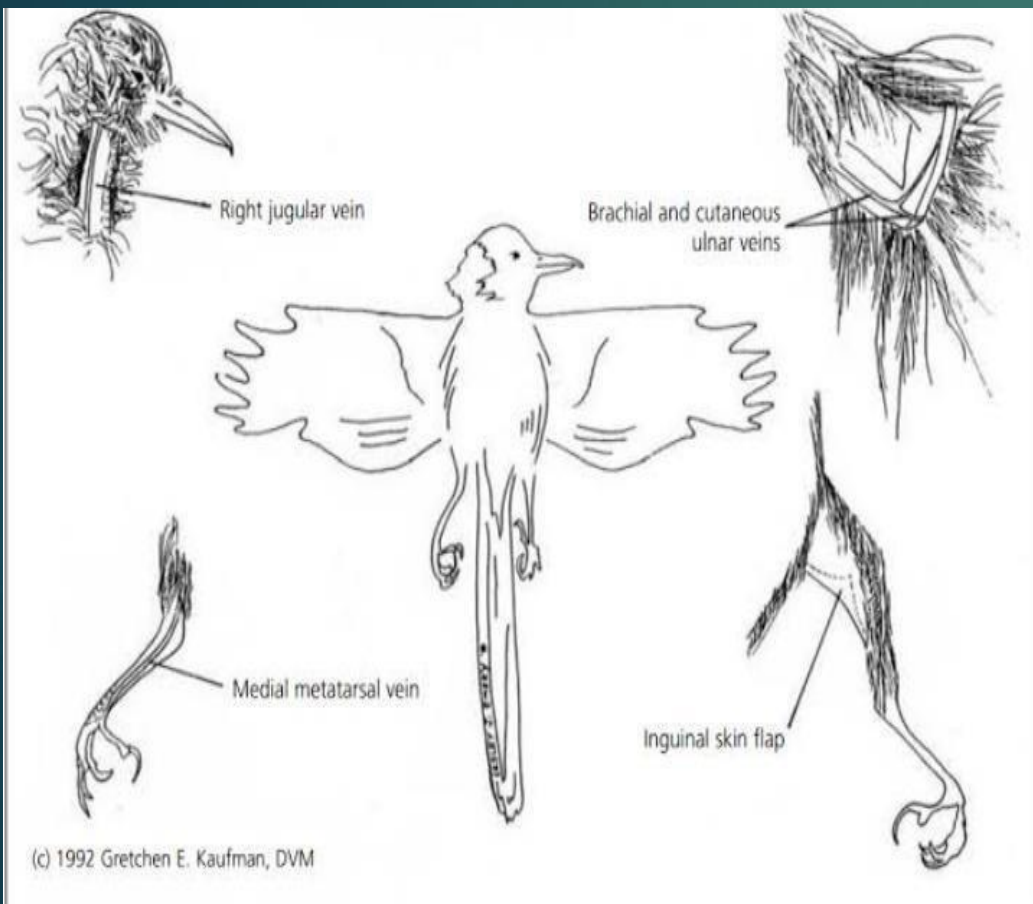
Restraint and control?!



Injection

- ▶ ***Intravenous(I/V): Right jugular vein, medial metatarsal vein in large breed.***
- ▶ ***Intramuscular (I/M): Pectoral muscle.***
- ▶ ***Subcutaneous (S/b): Inguinal Region***



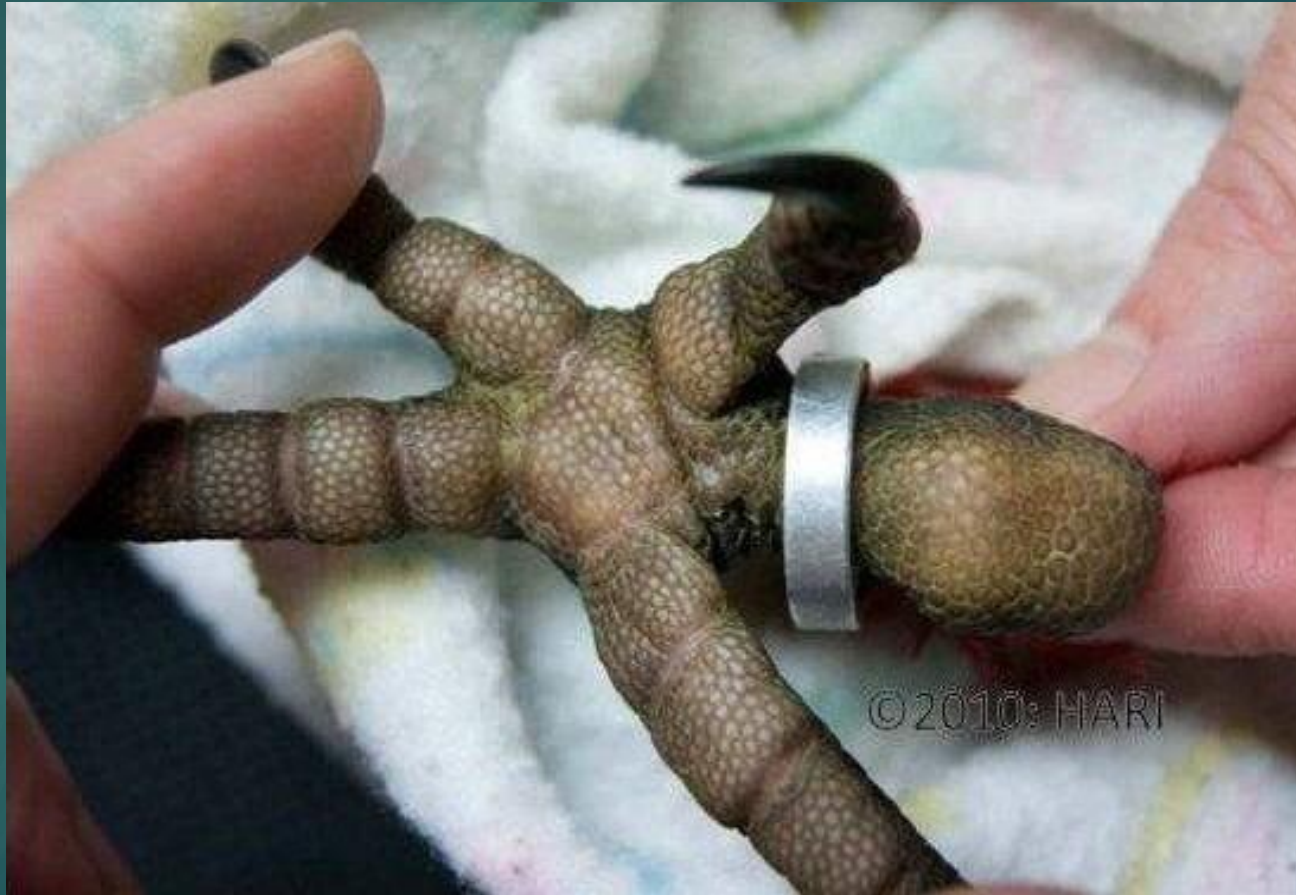

Cases!!

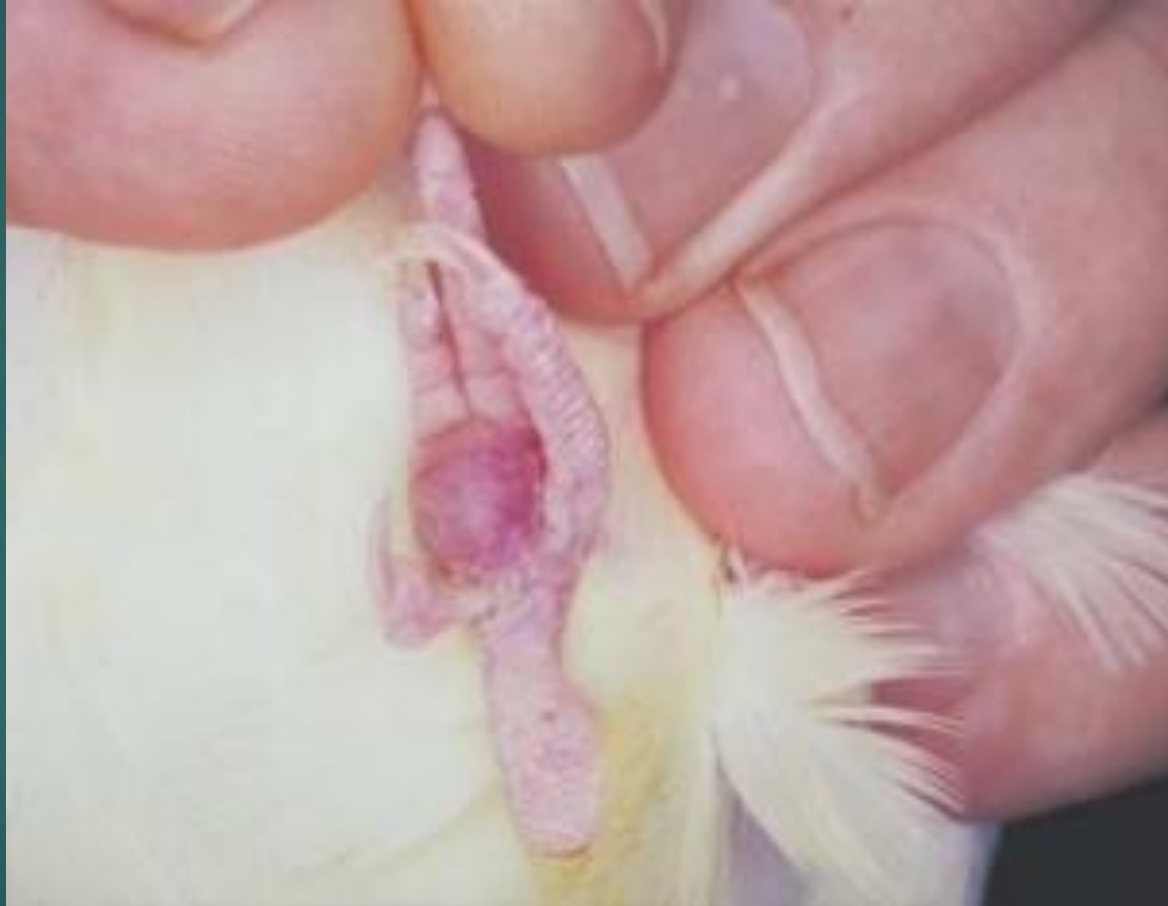
-Egg lices



Pododermatitis(pumble foot)



Advanced pumble foot



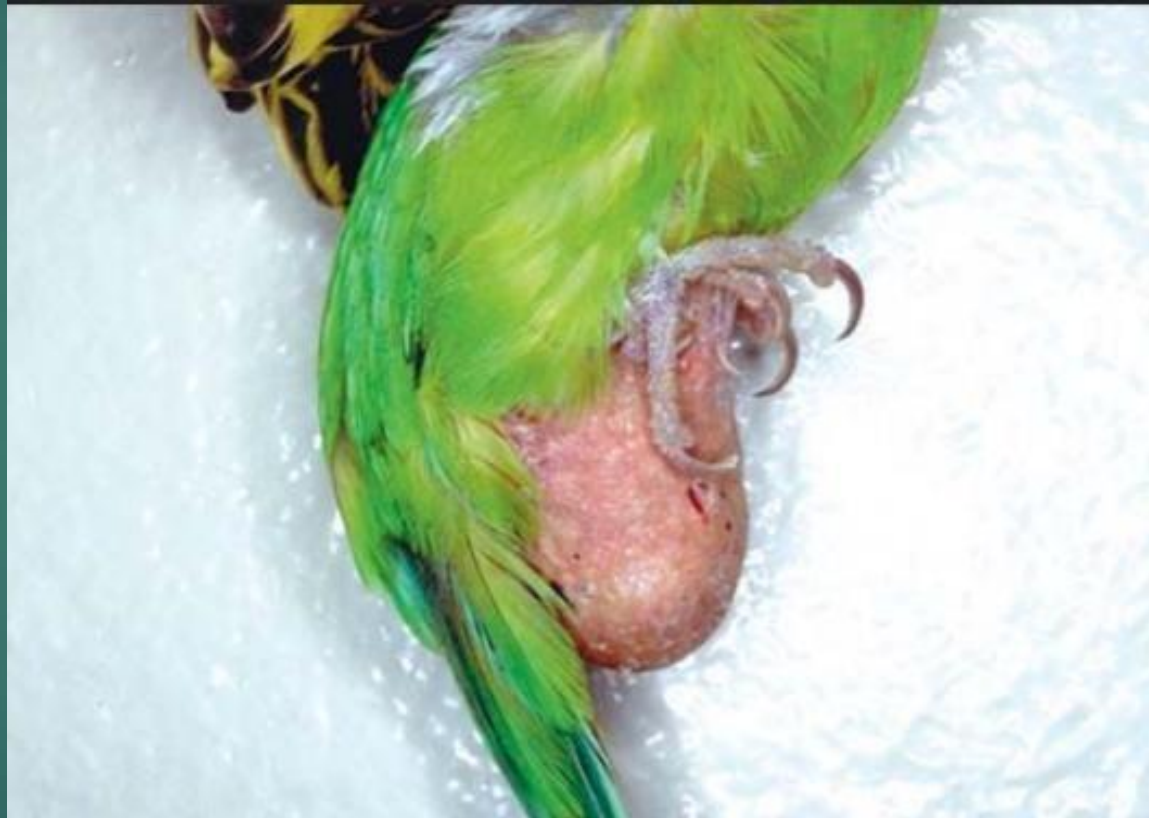Swelling above beak



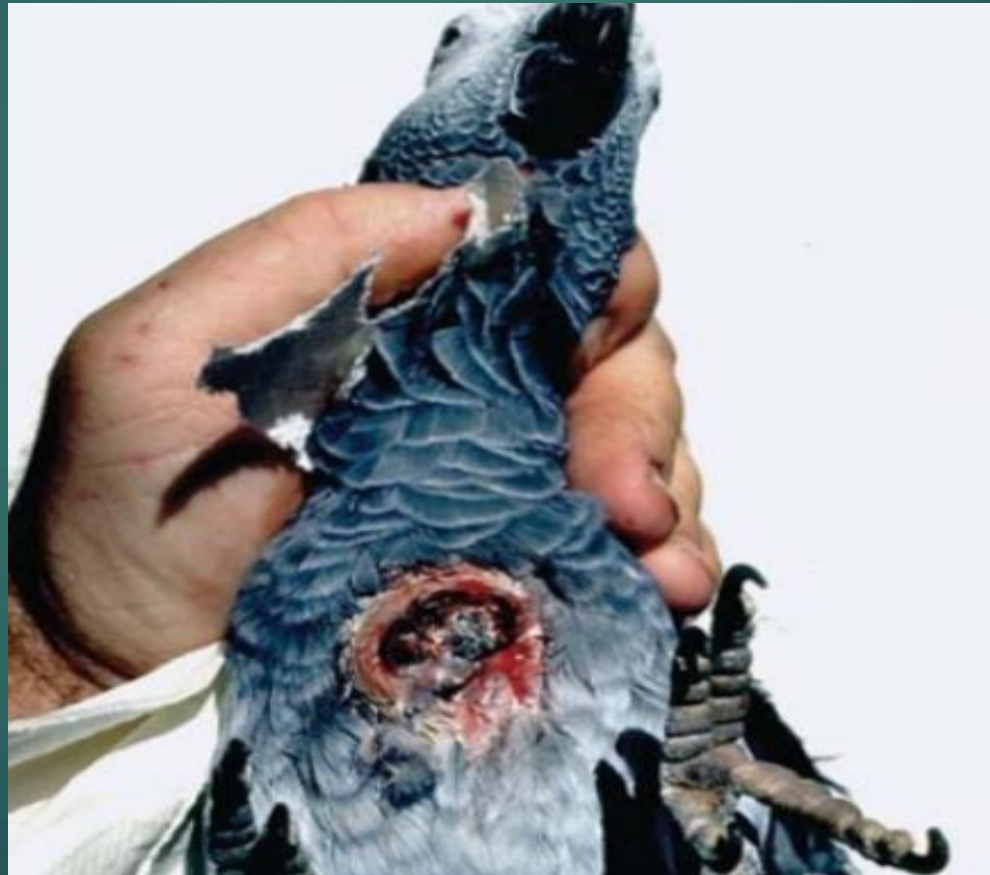Fungal infection



Hernia



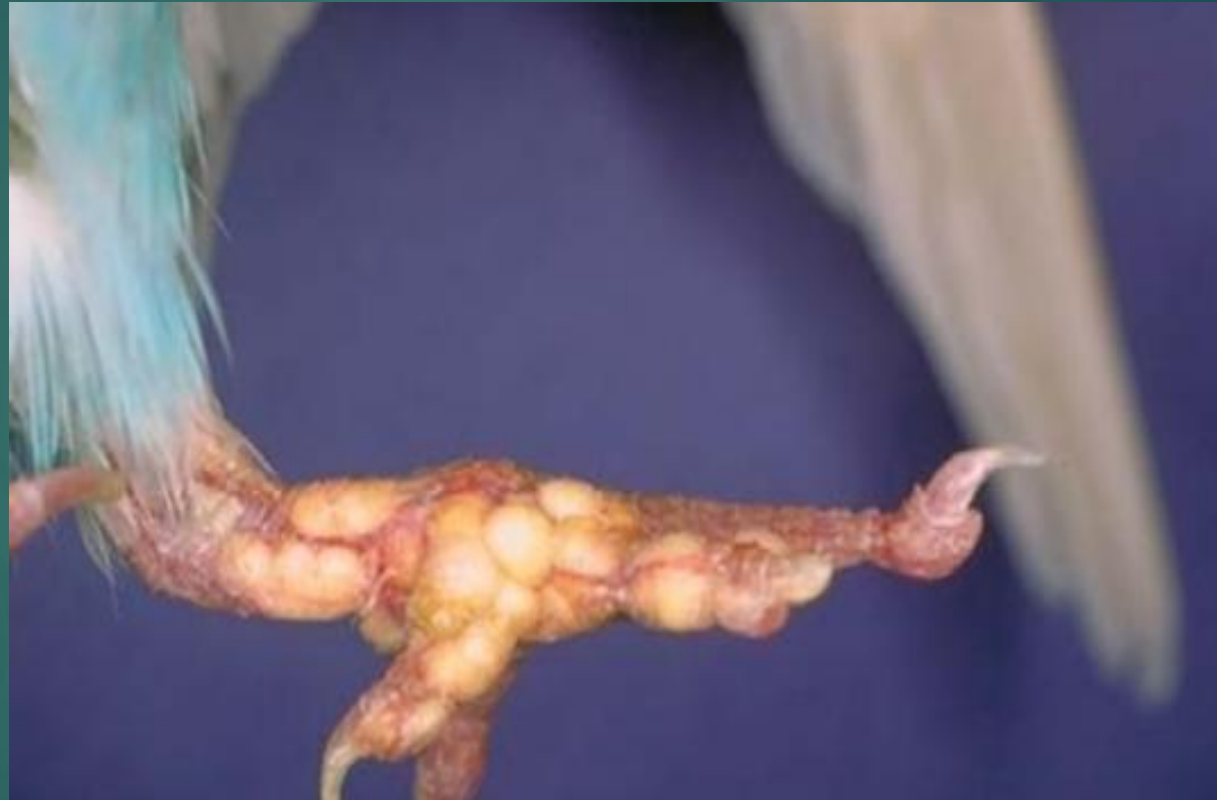Sternal ulcer

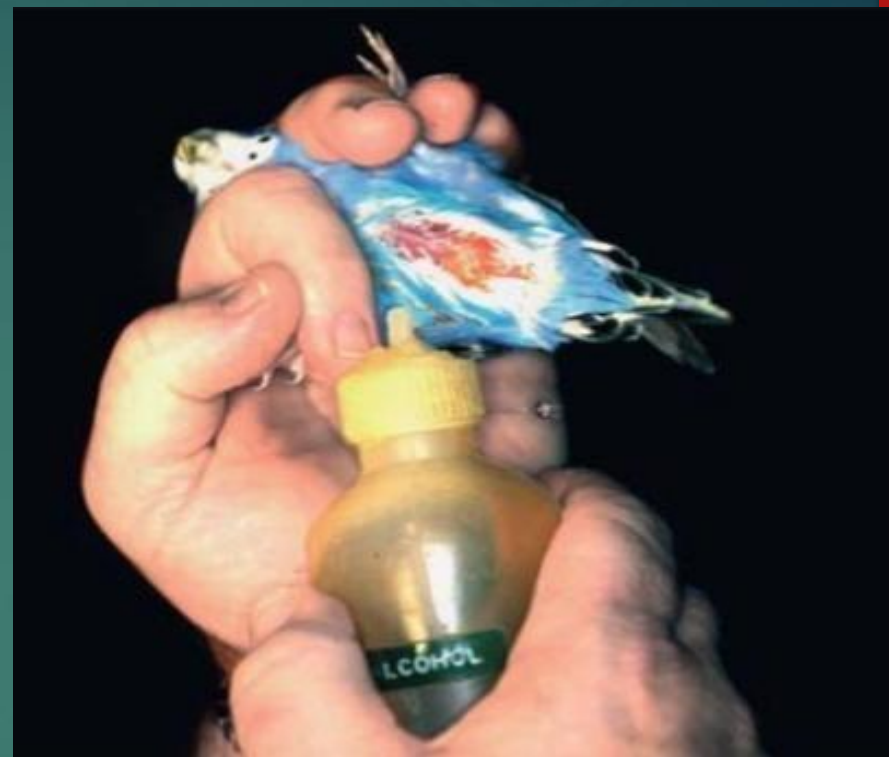

Thick nails



Gout tophi





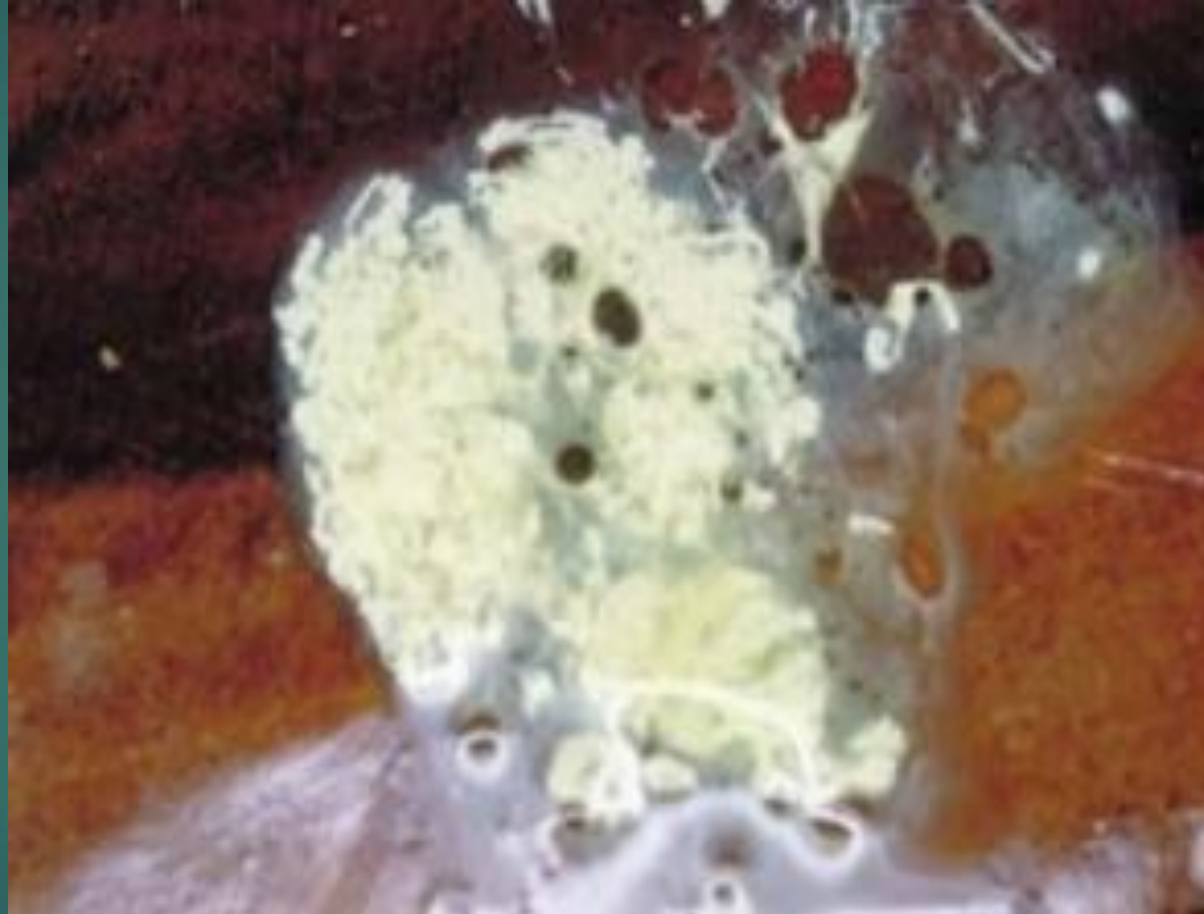
Accumulation of fat



Conjunctivitis (malnutrition)



Kidney Disease (polyurates with fat)



Egg bound



BPFD(Circovirus)



Thanks for your listening

H

